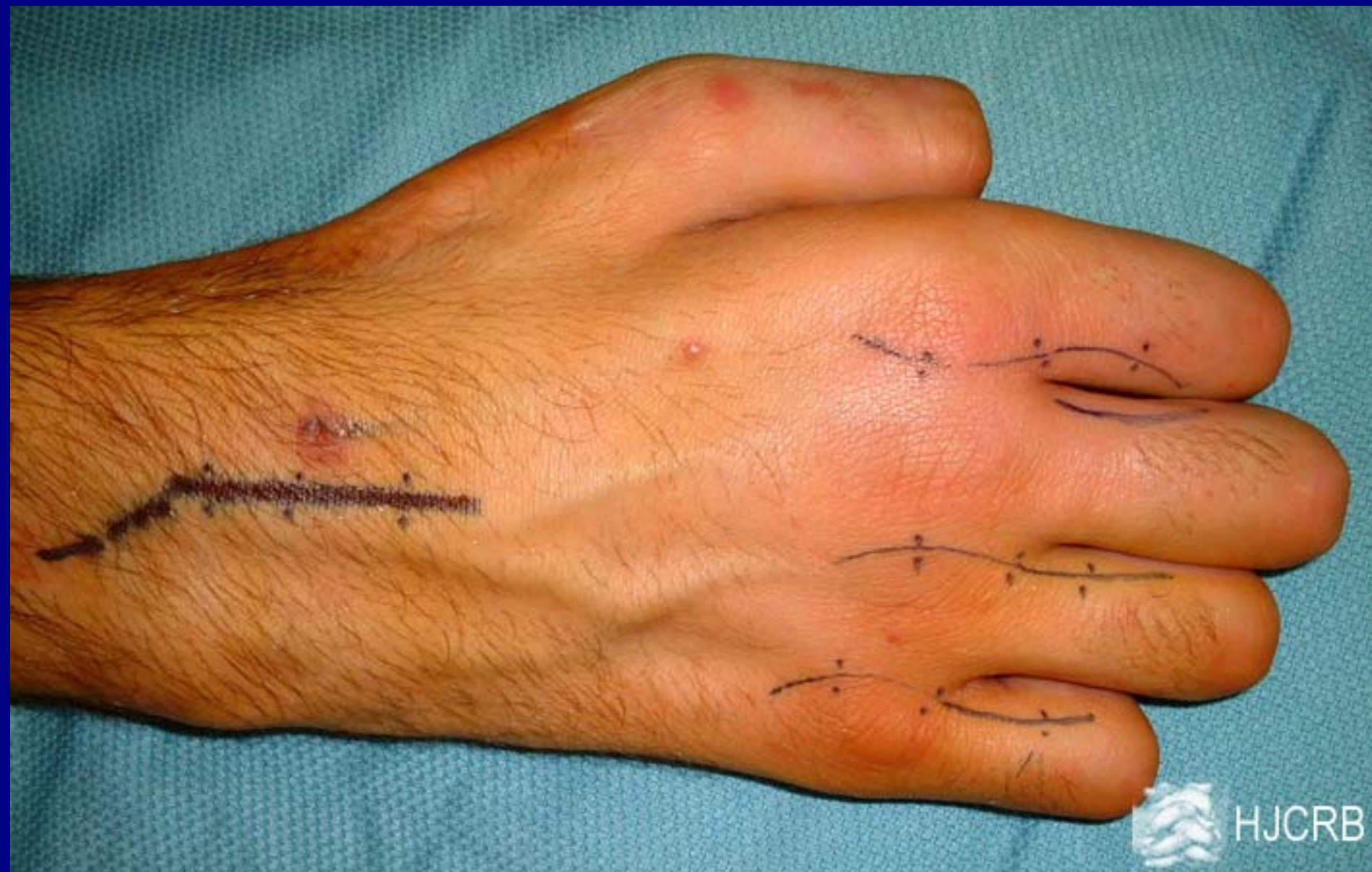
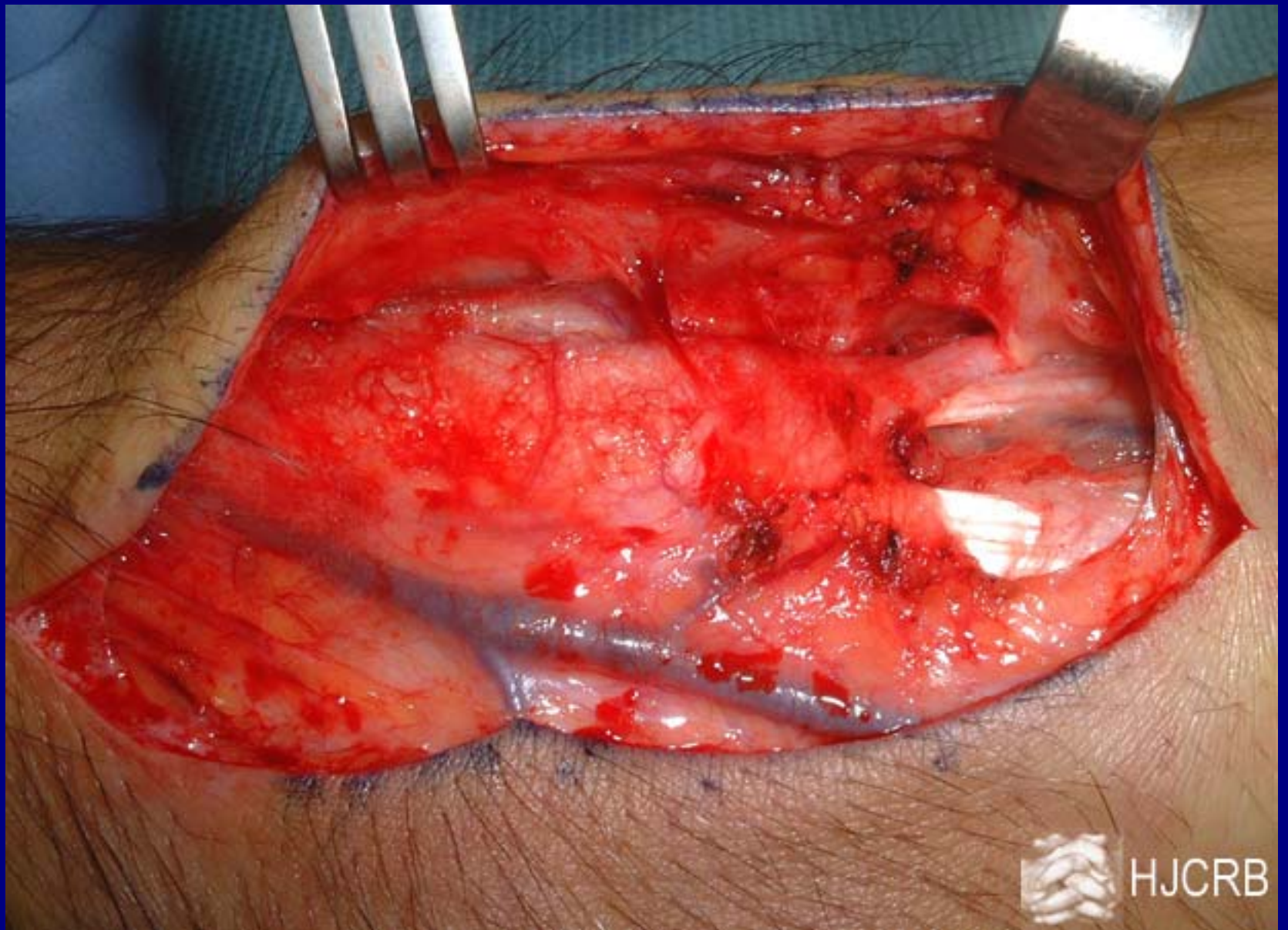

Combined high median and ulnar palsy
Clawing + Adduction deformity of thumb

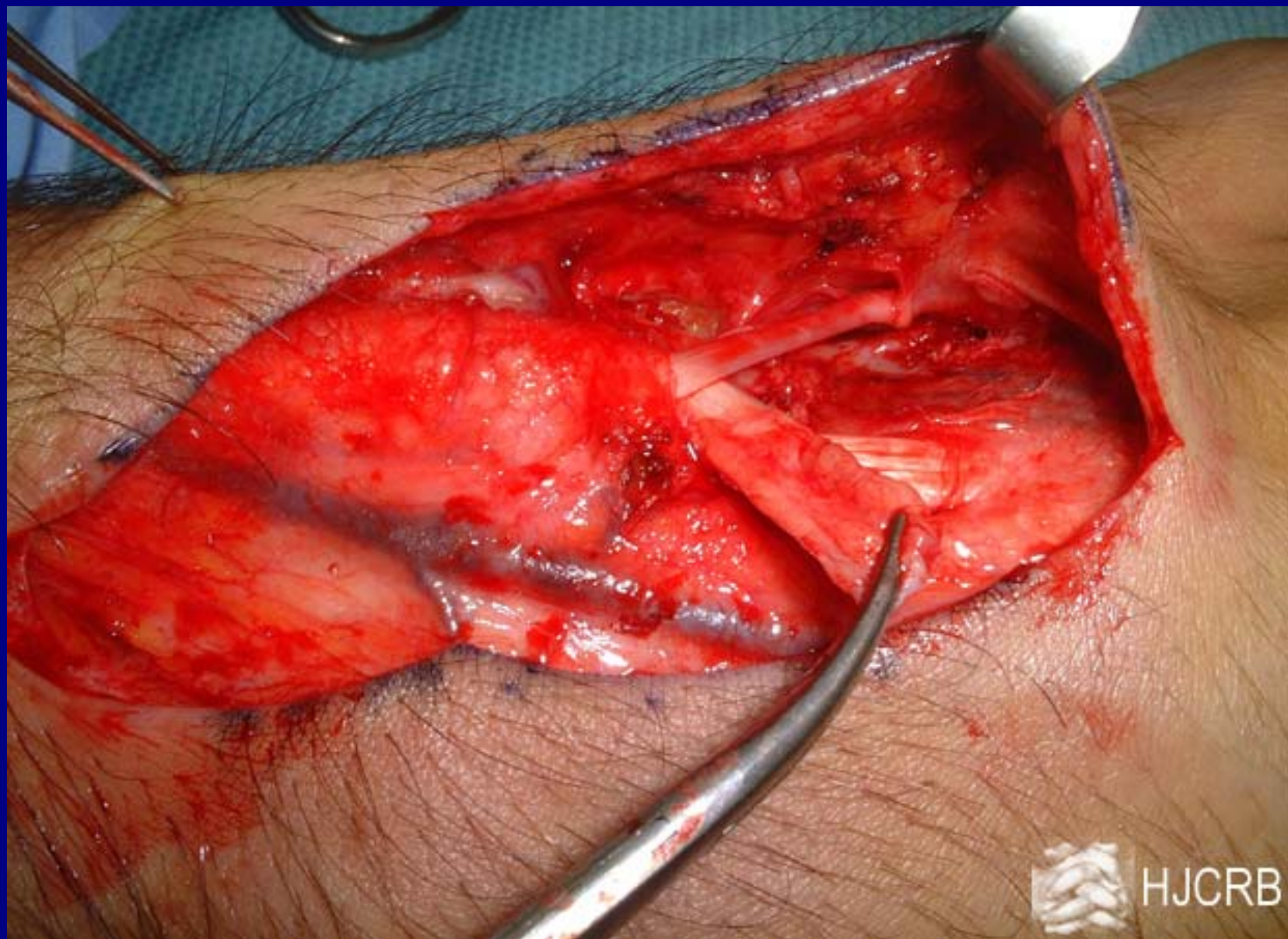ECRL – PL graft – Extensor hood

EIP opponensplasty

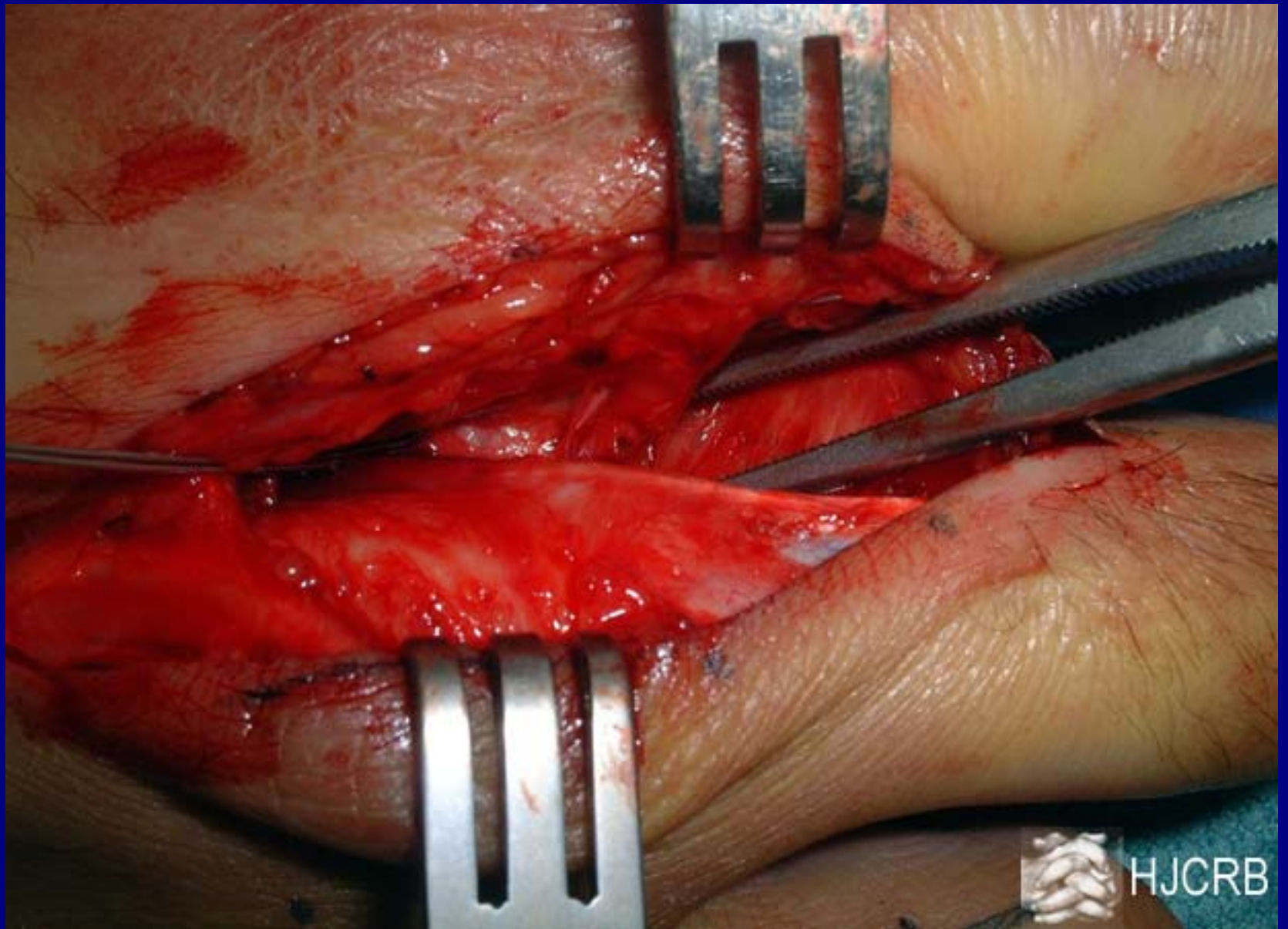




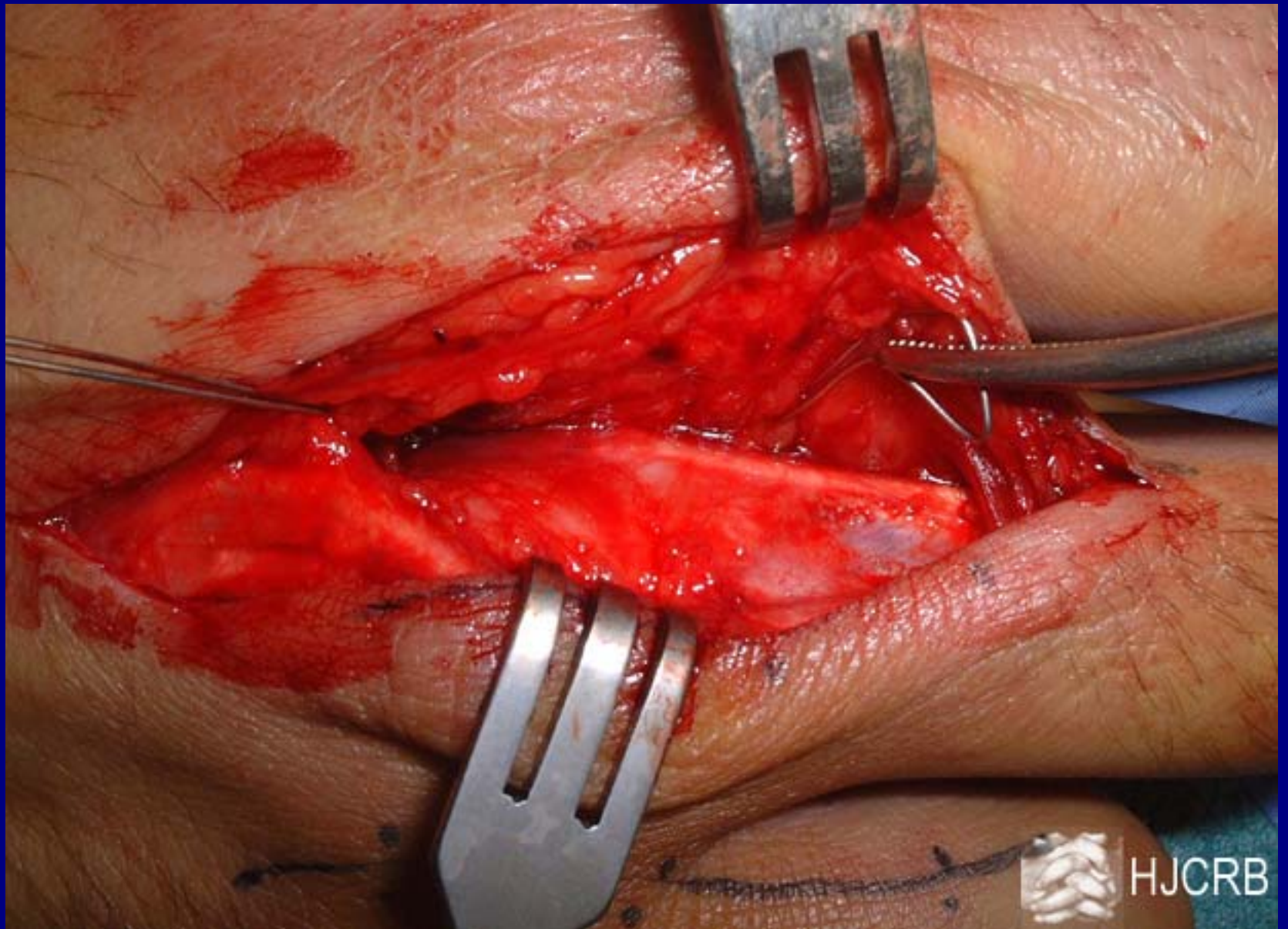
HJCRB



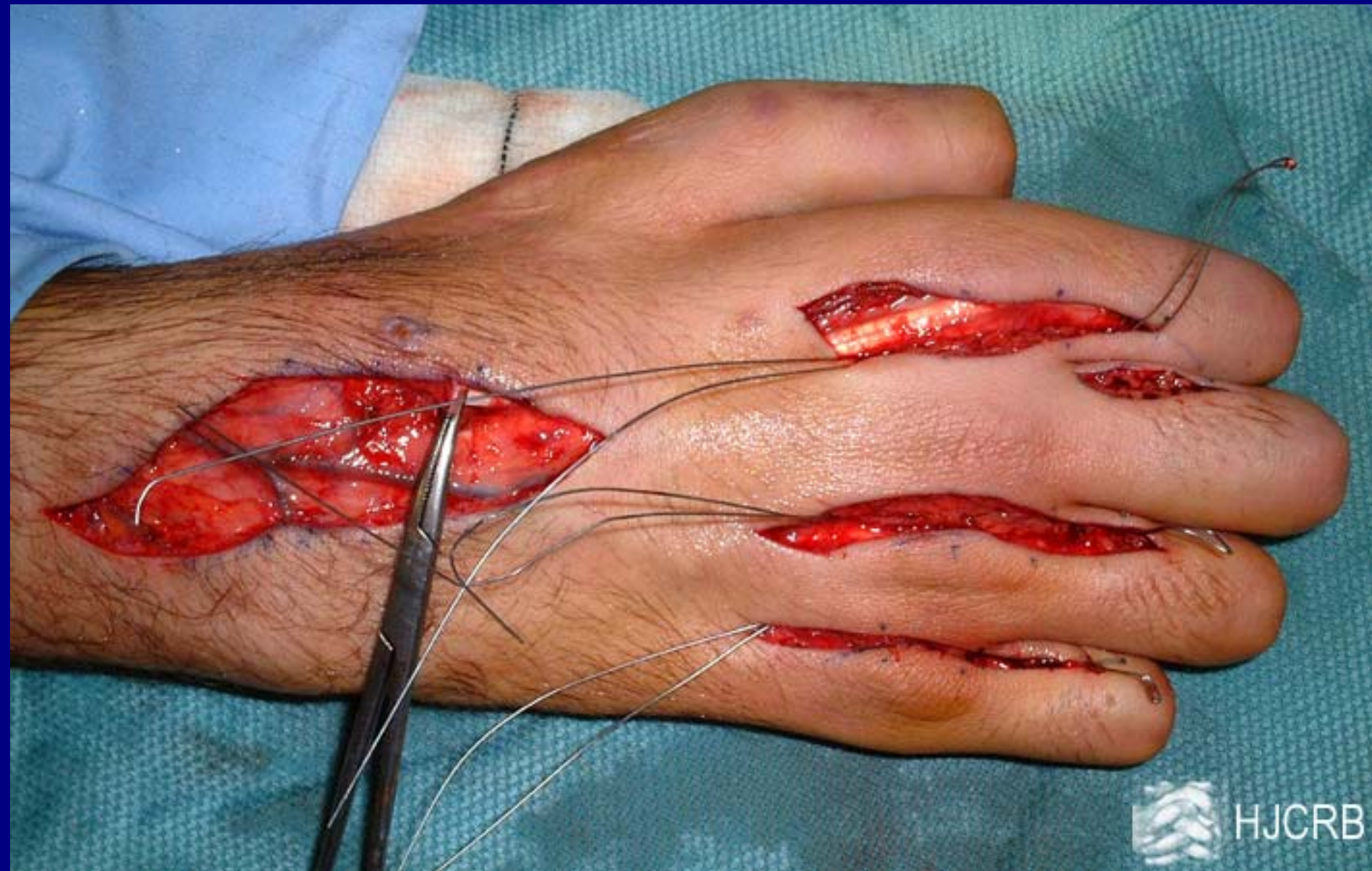HJCRB

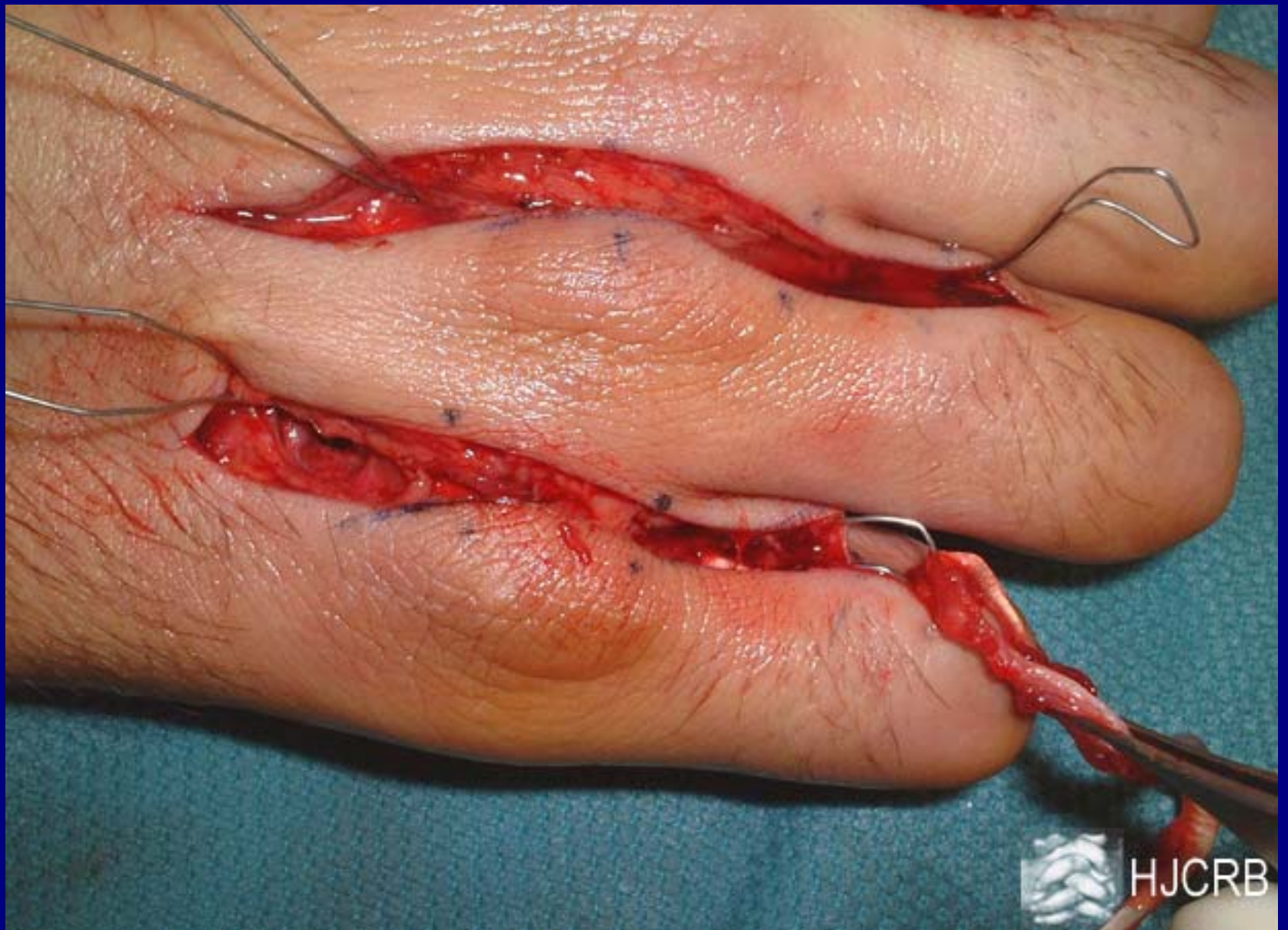

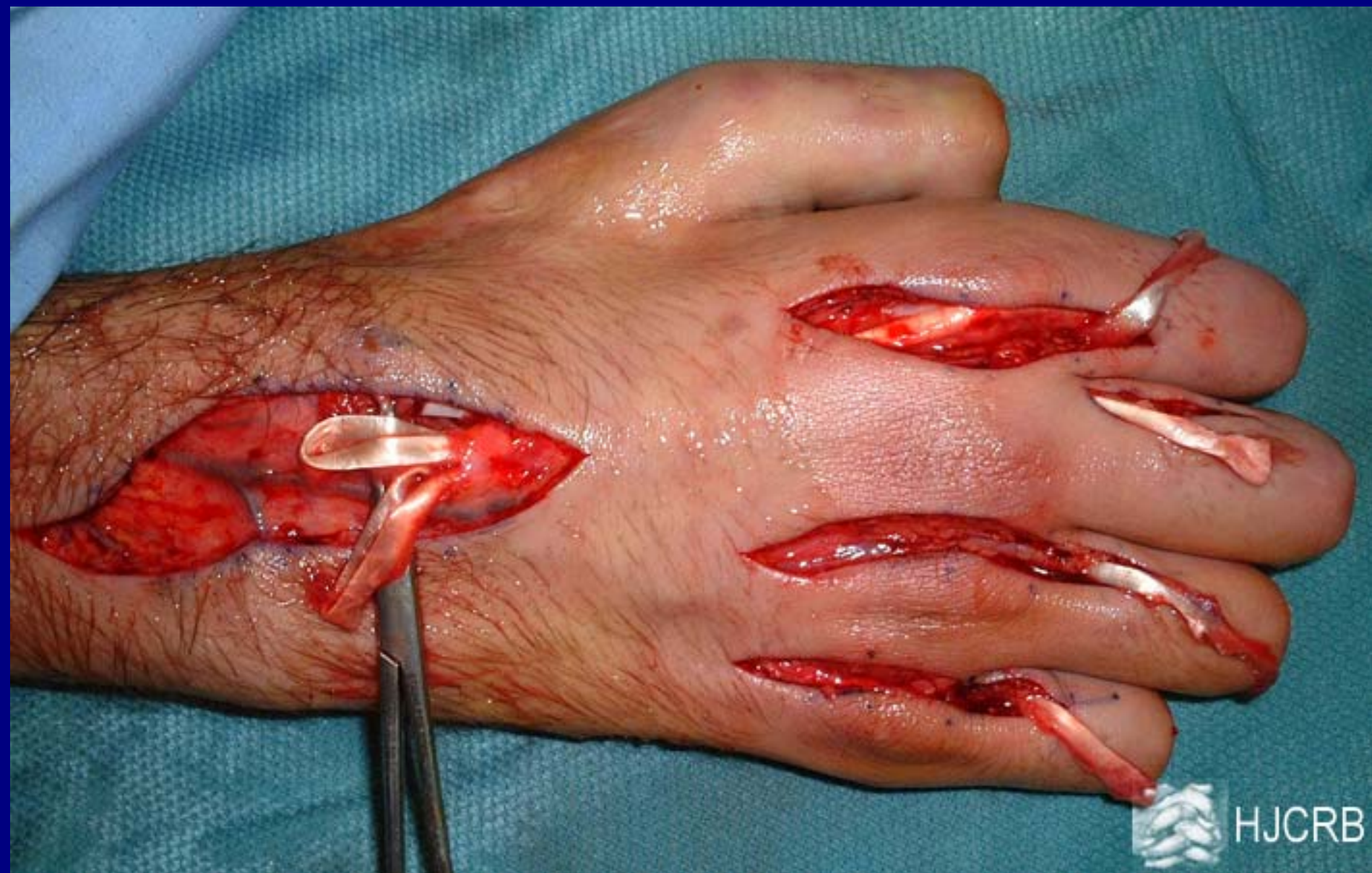HJCRB

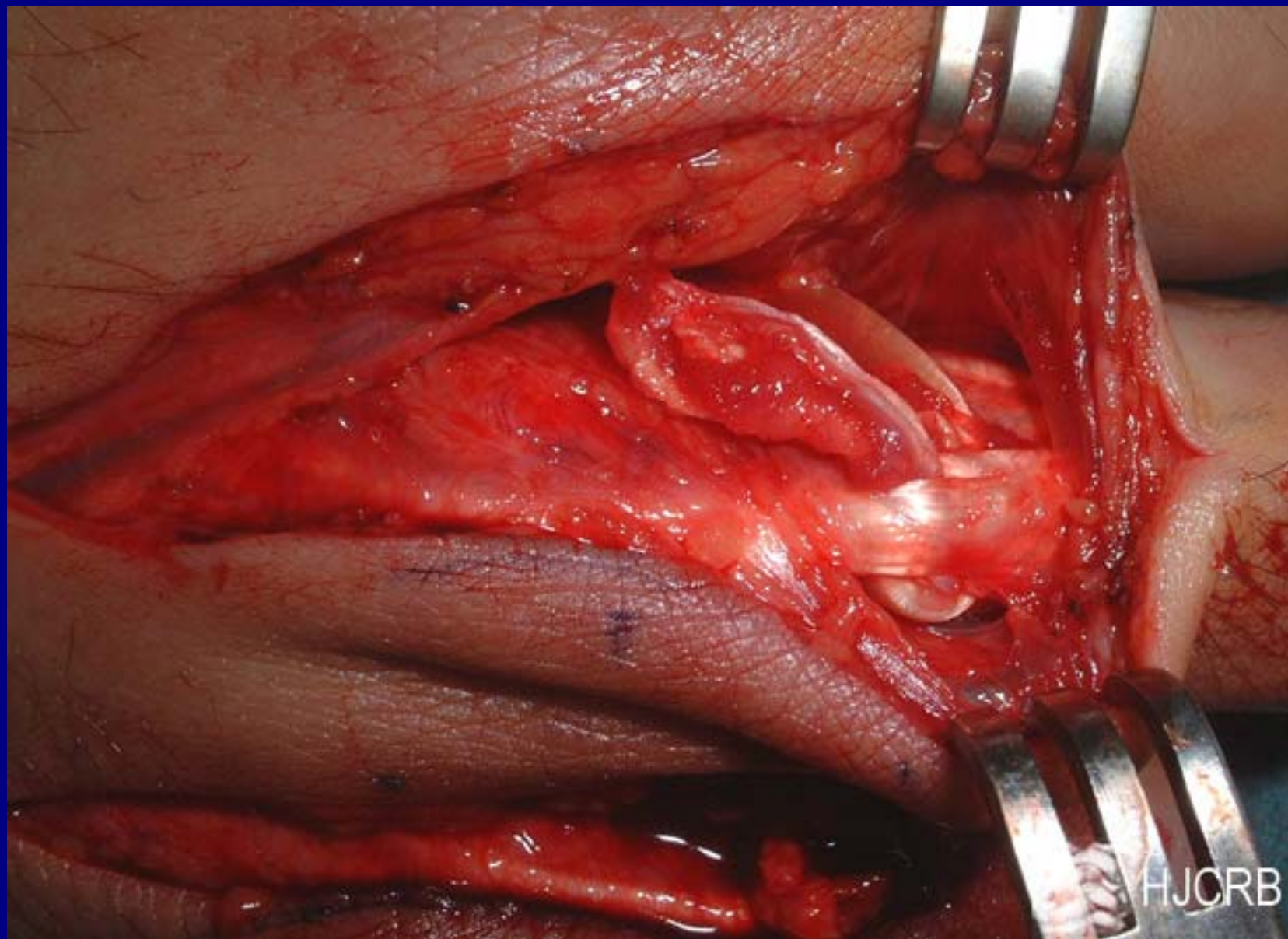


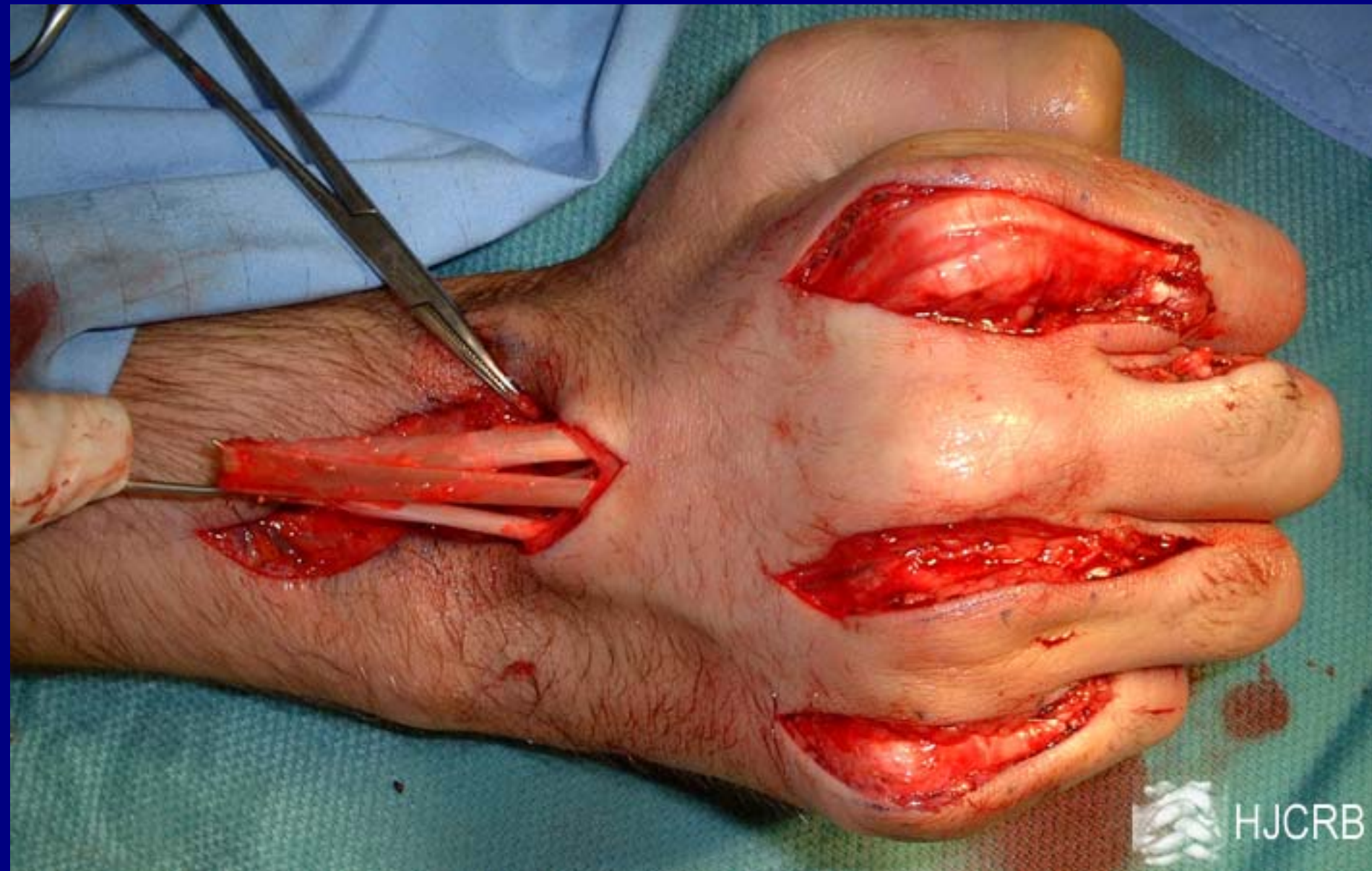HJCRB

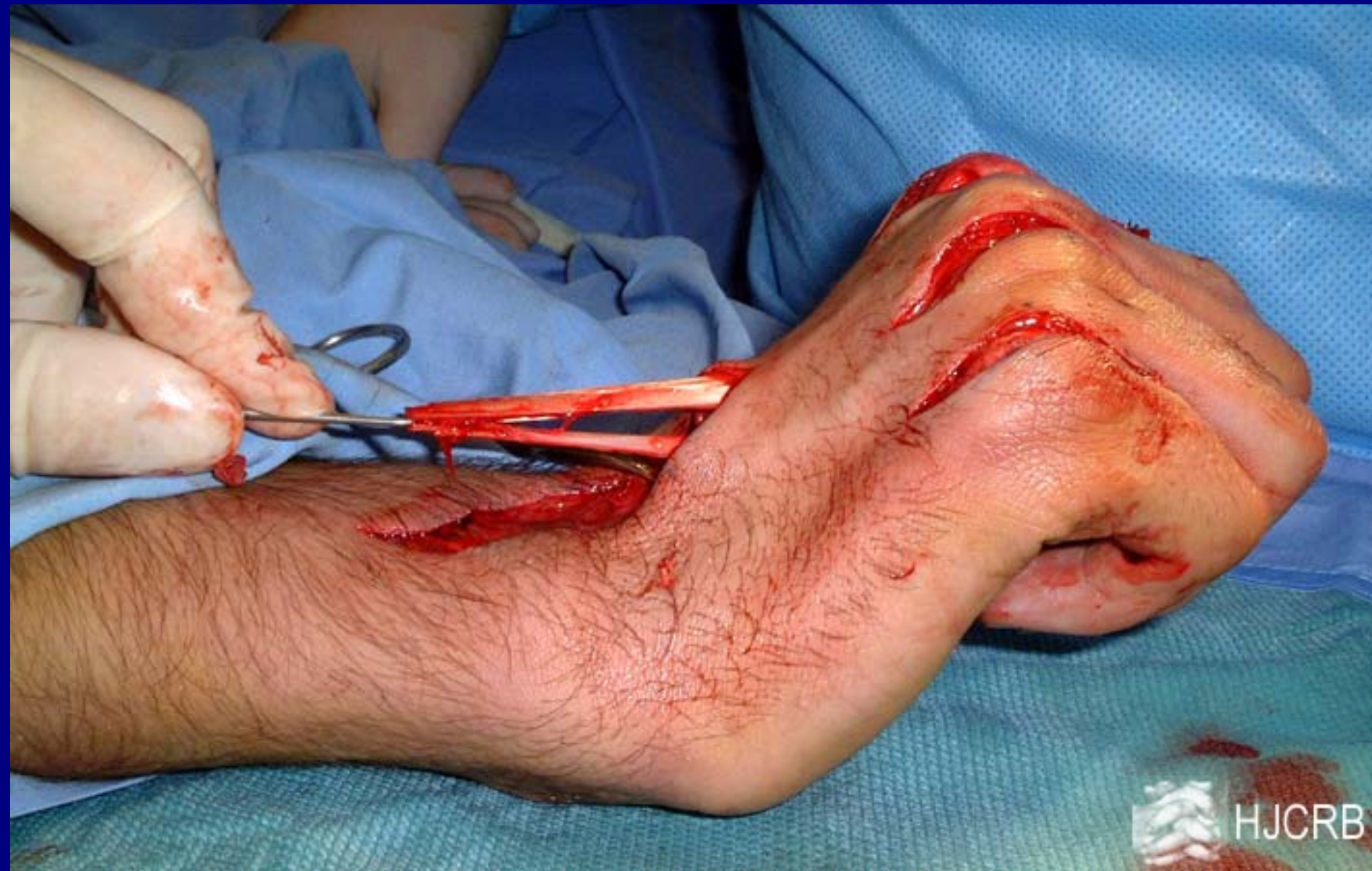

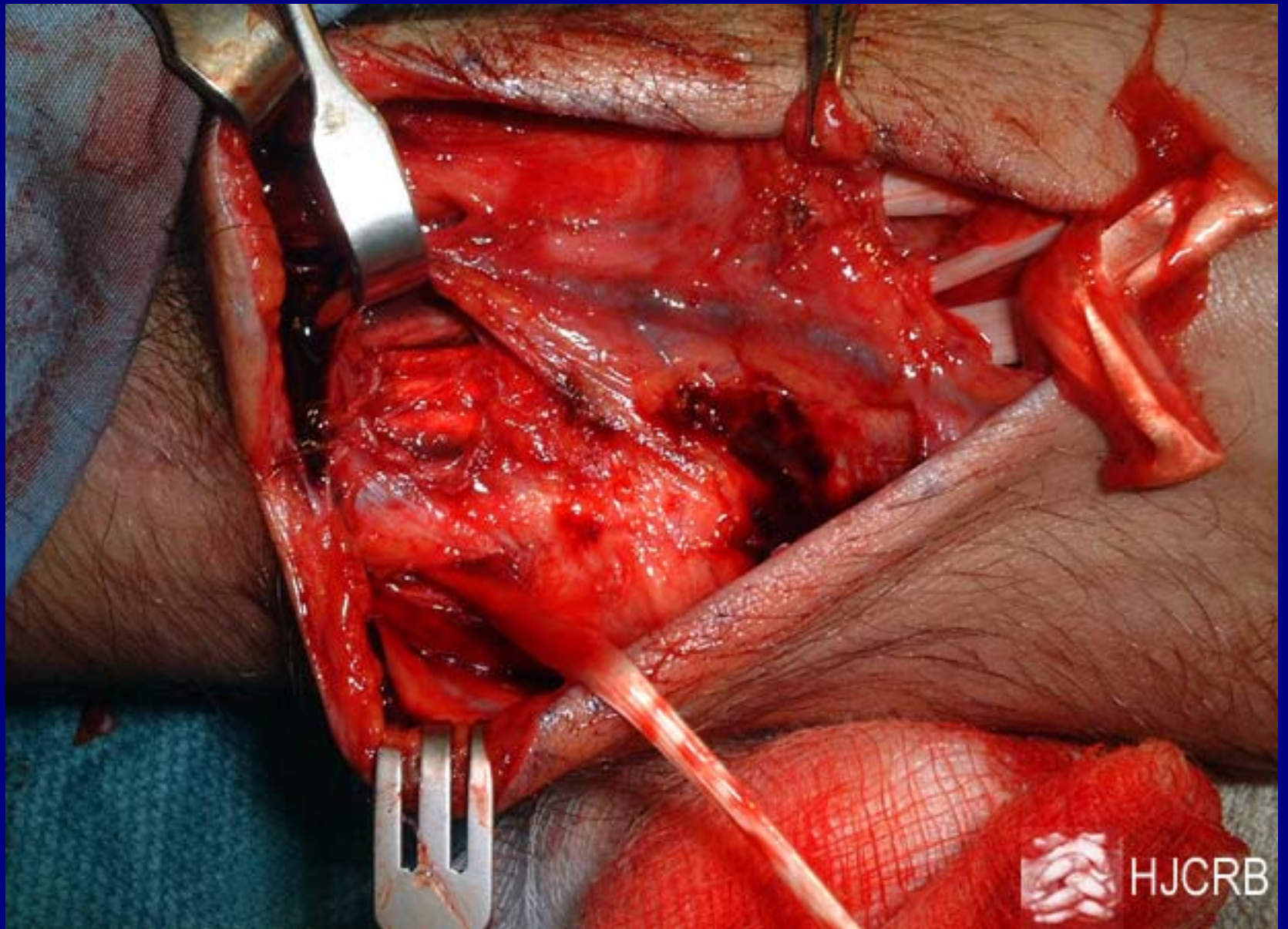



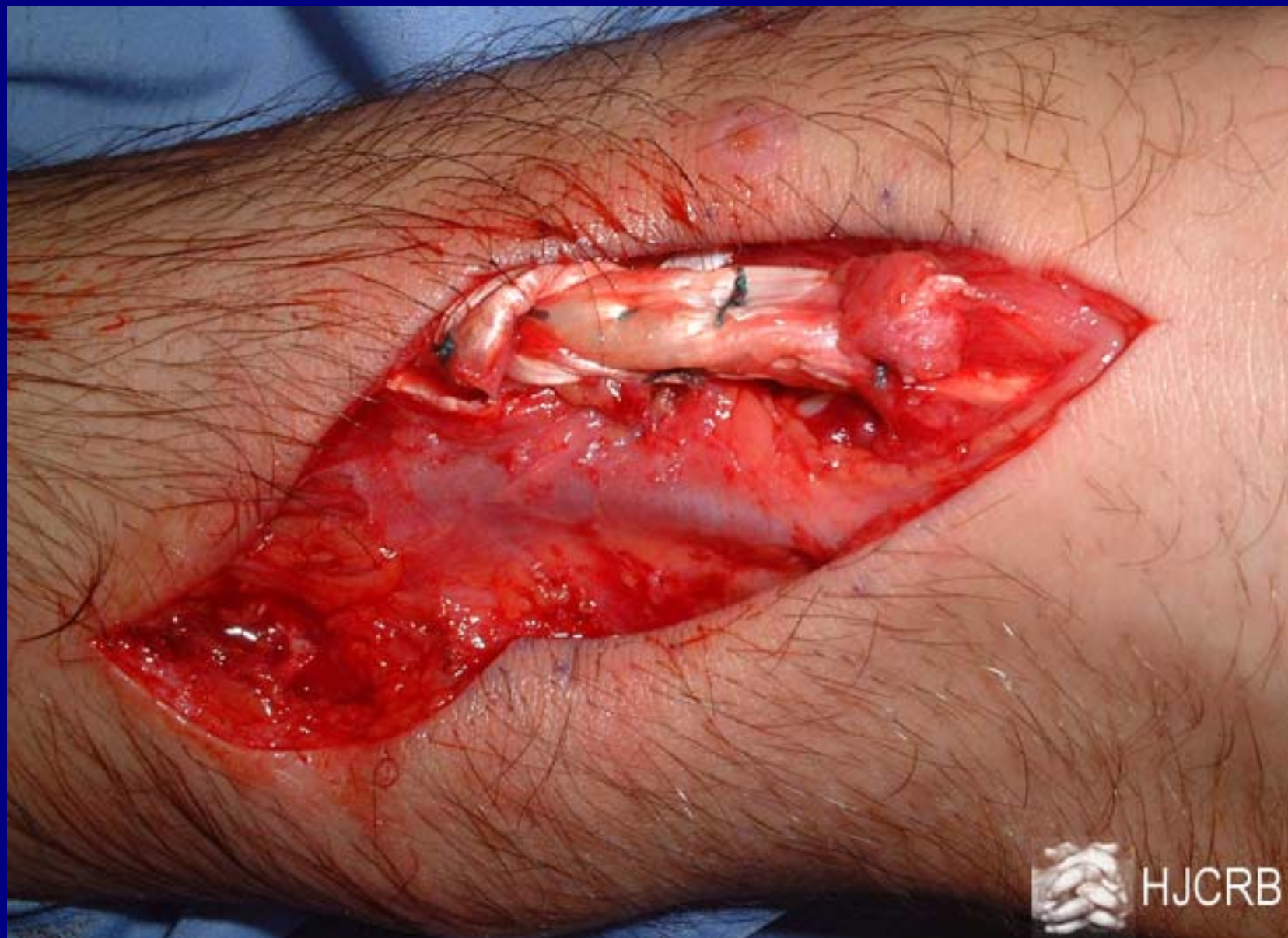


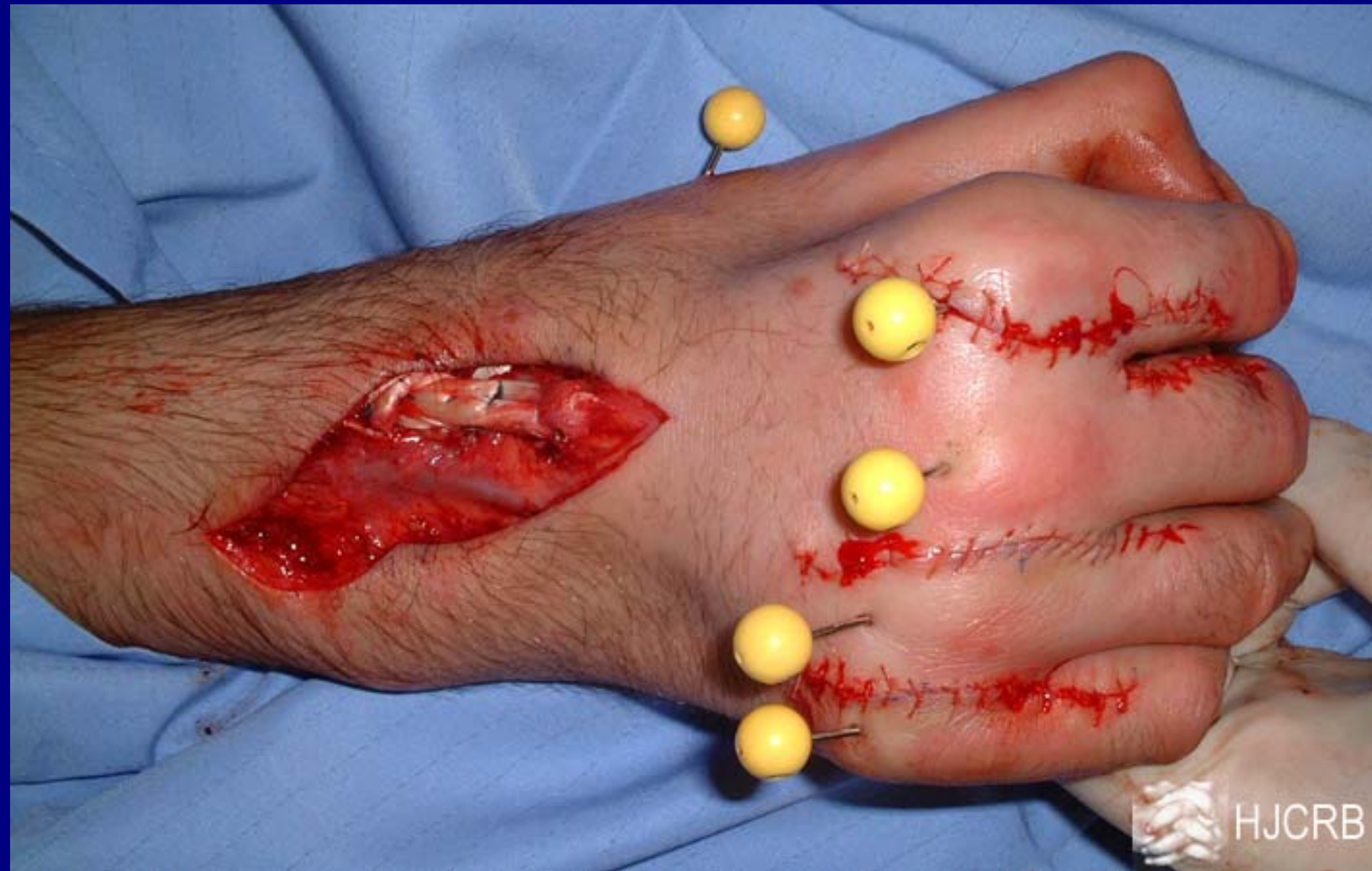









HJCRB