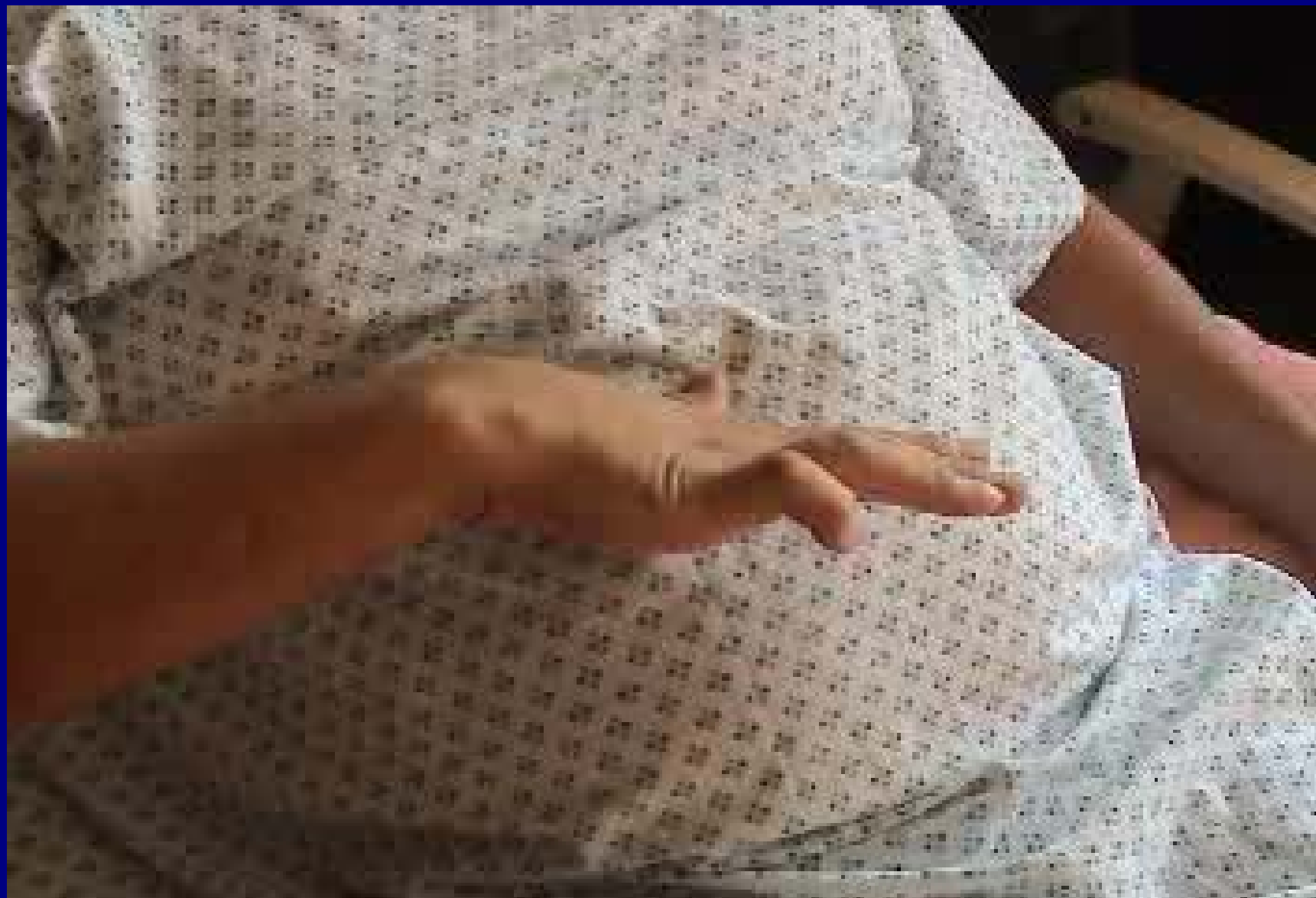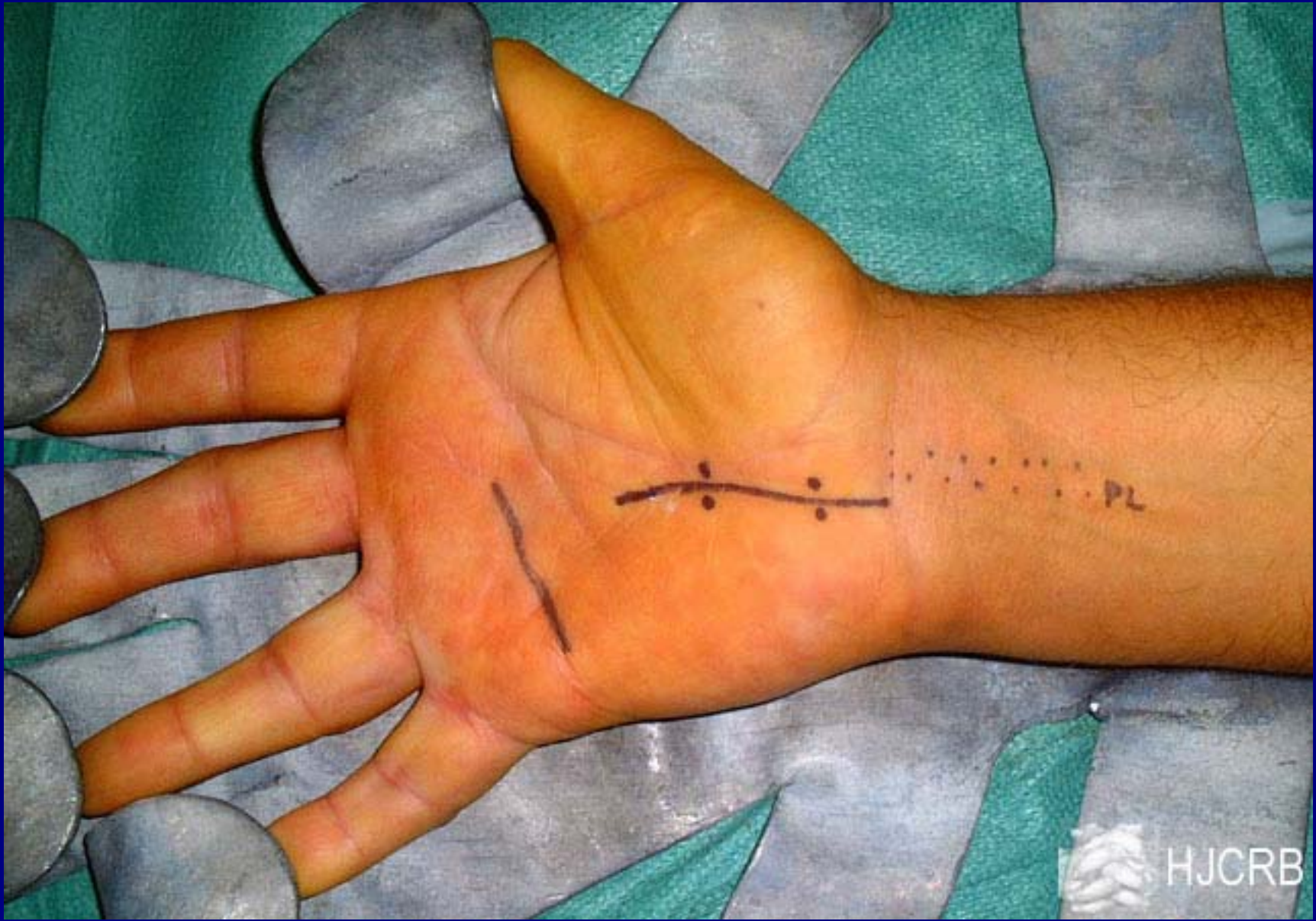


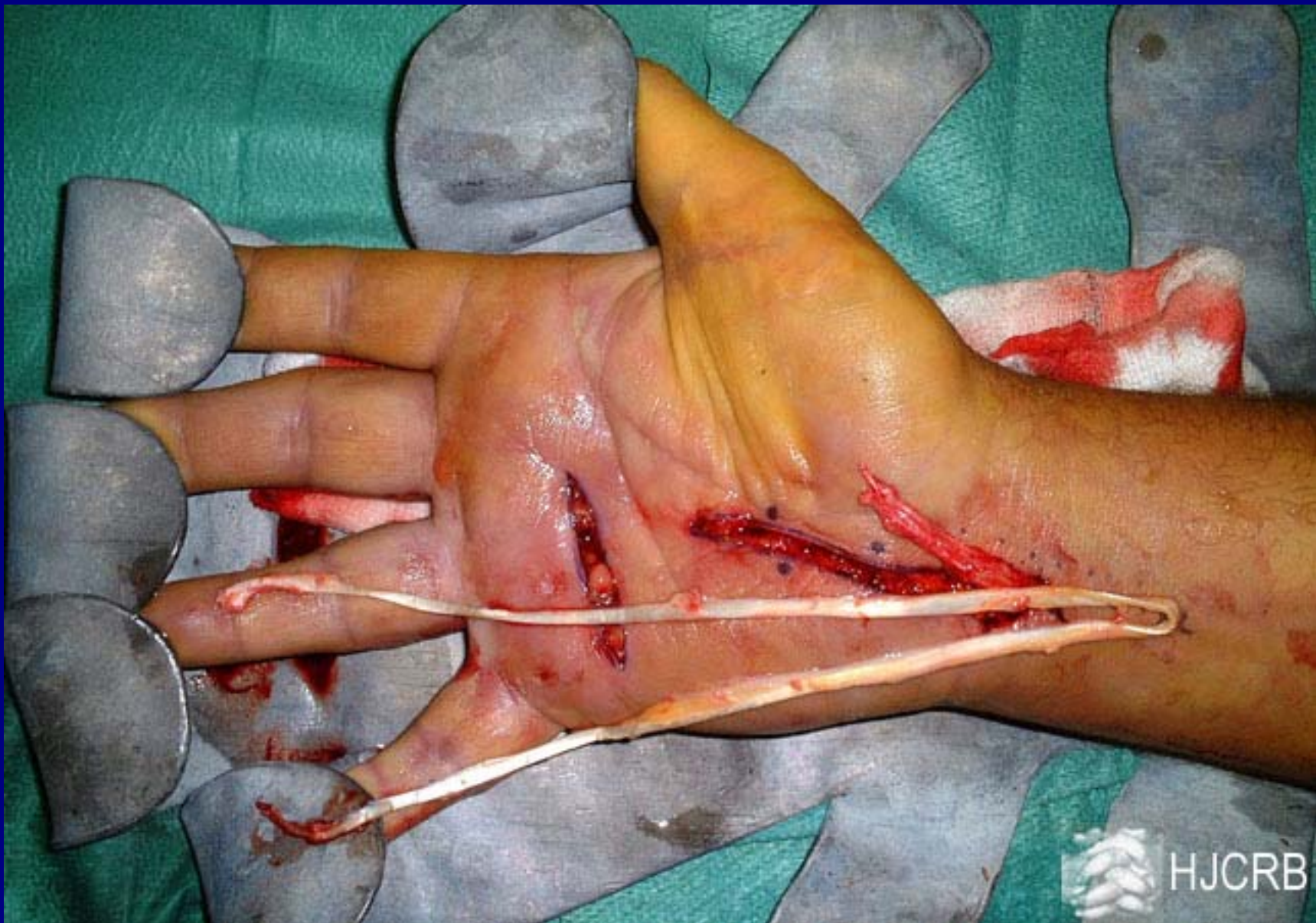Clawing after a high ulnar nerve injury. Weak FDP function making FDS transfer unsuitable

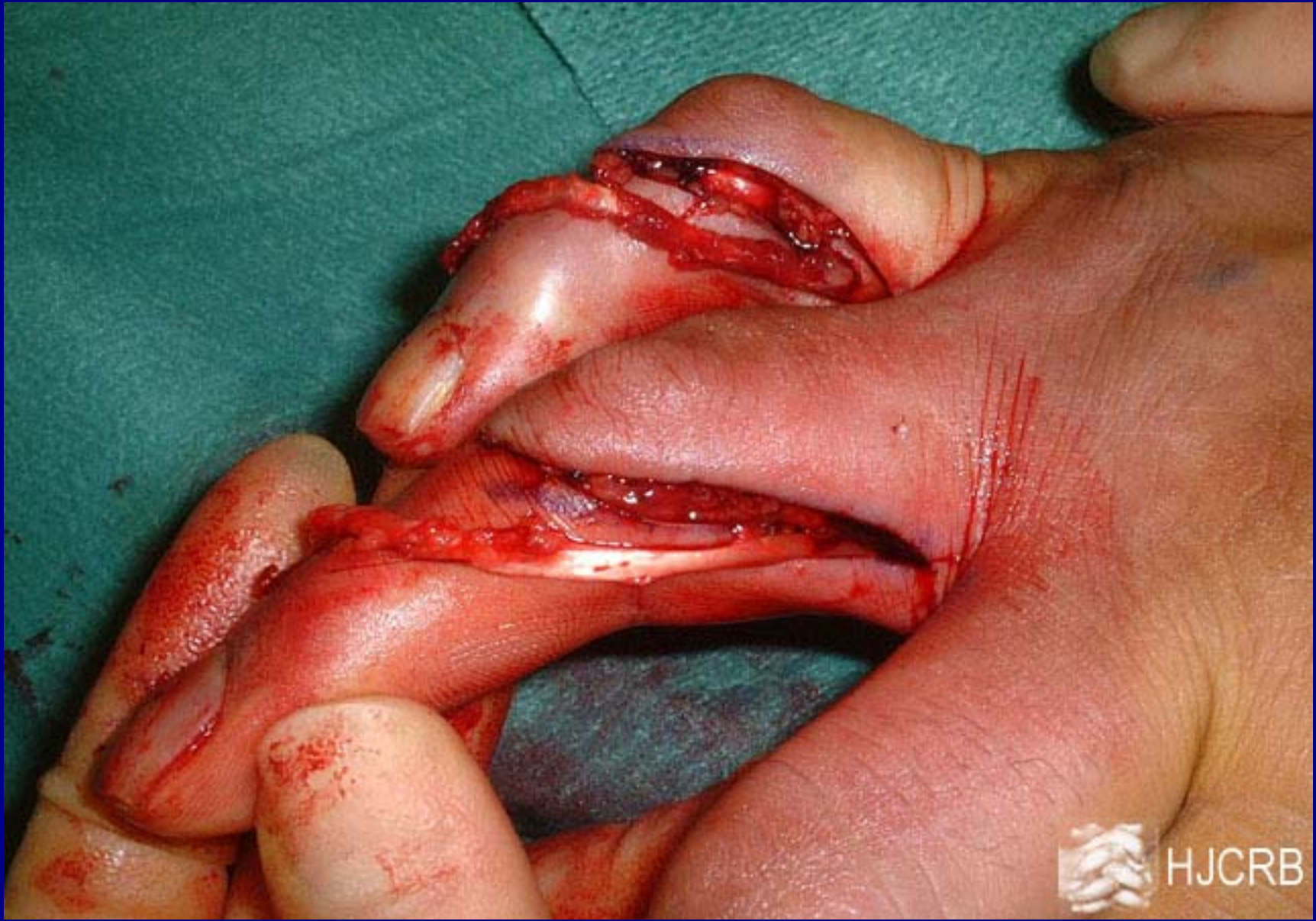PL to extensor hoods via plantaris graft

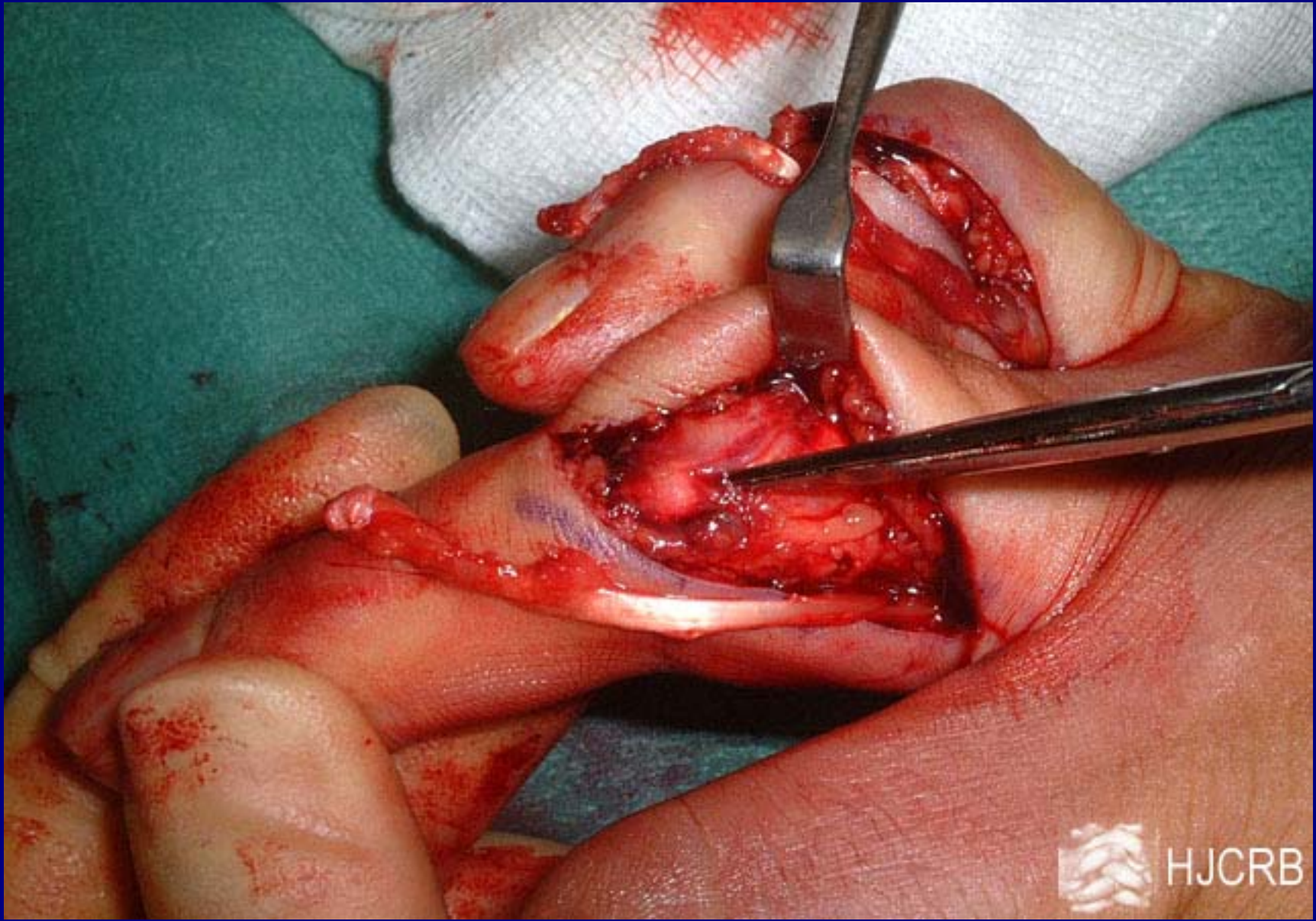


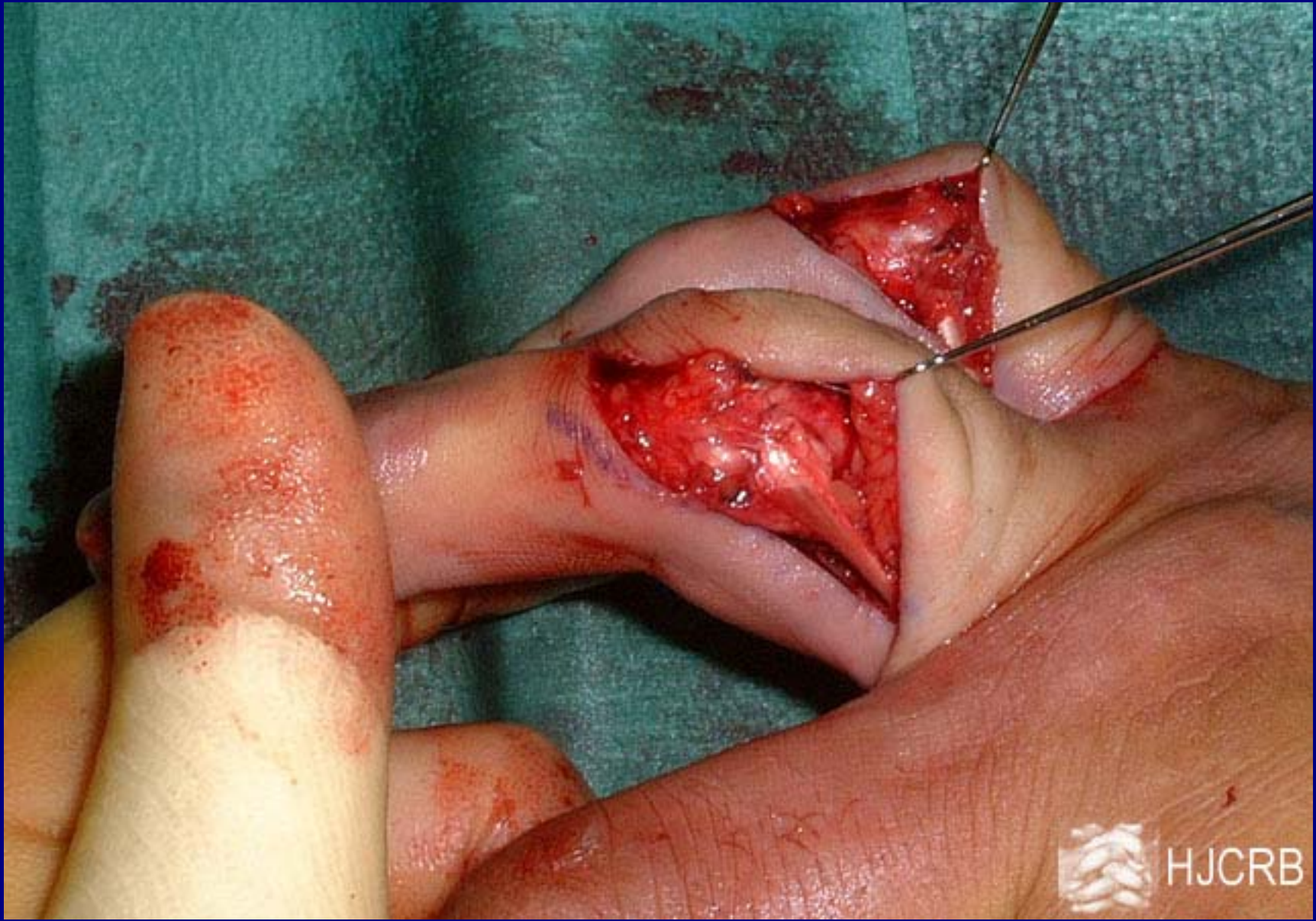
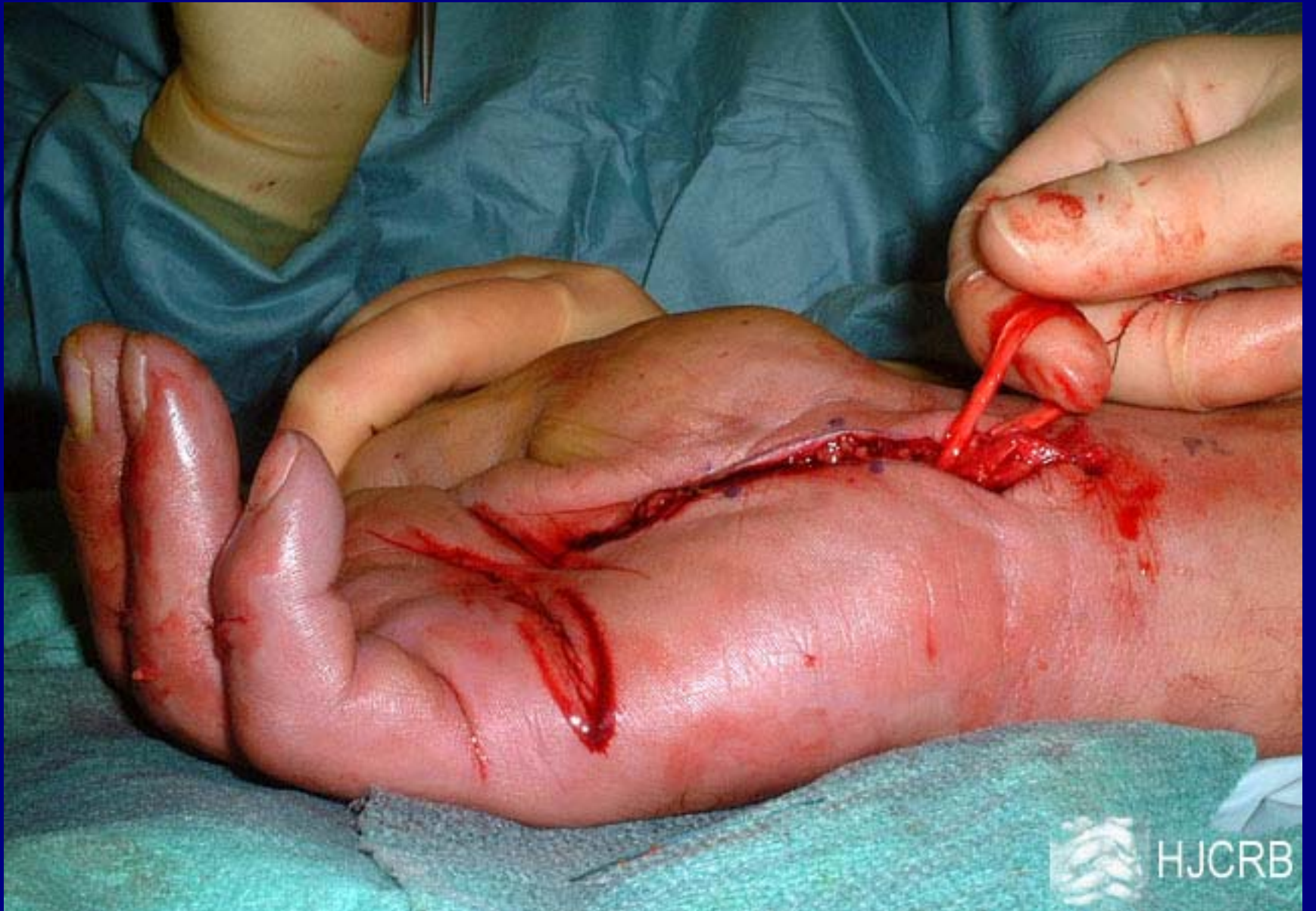HJCRB











HJCRB





