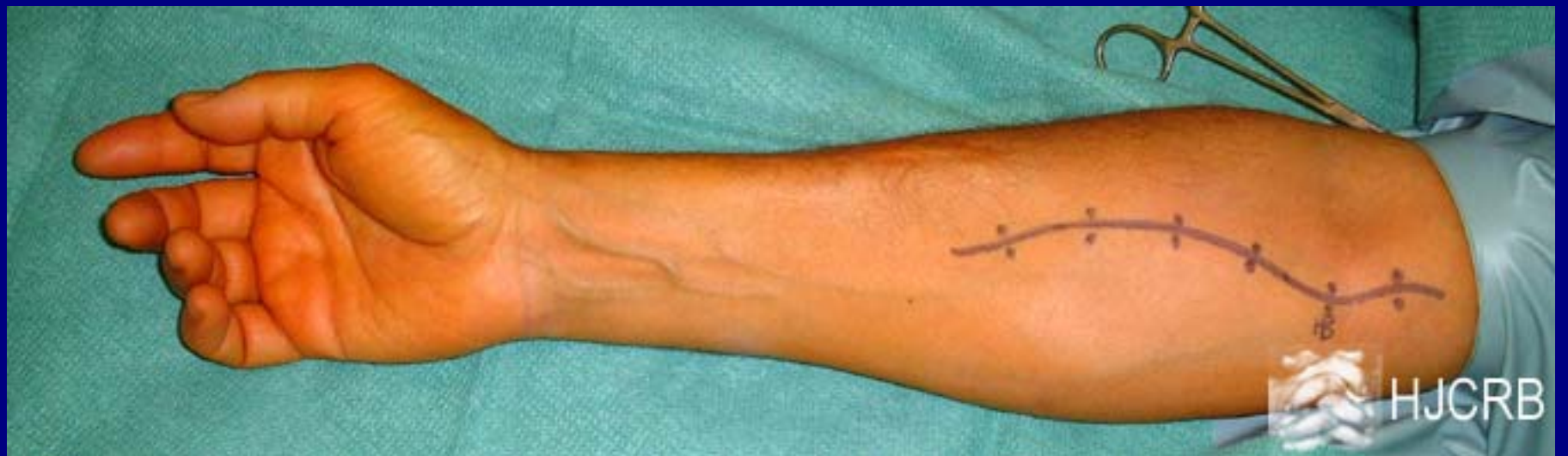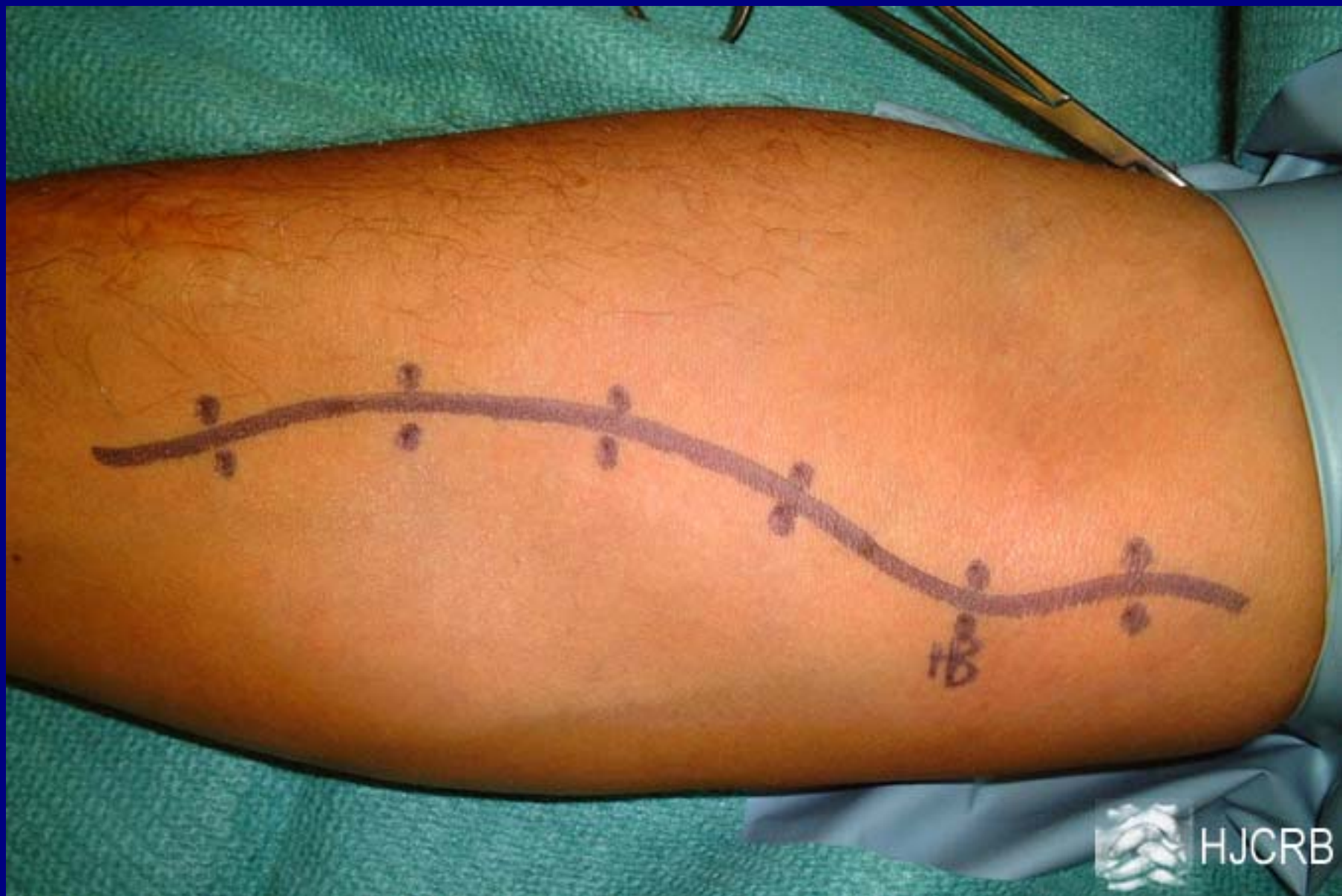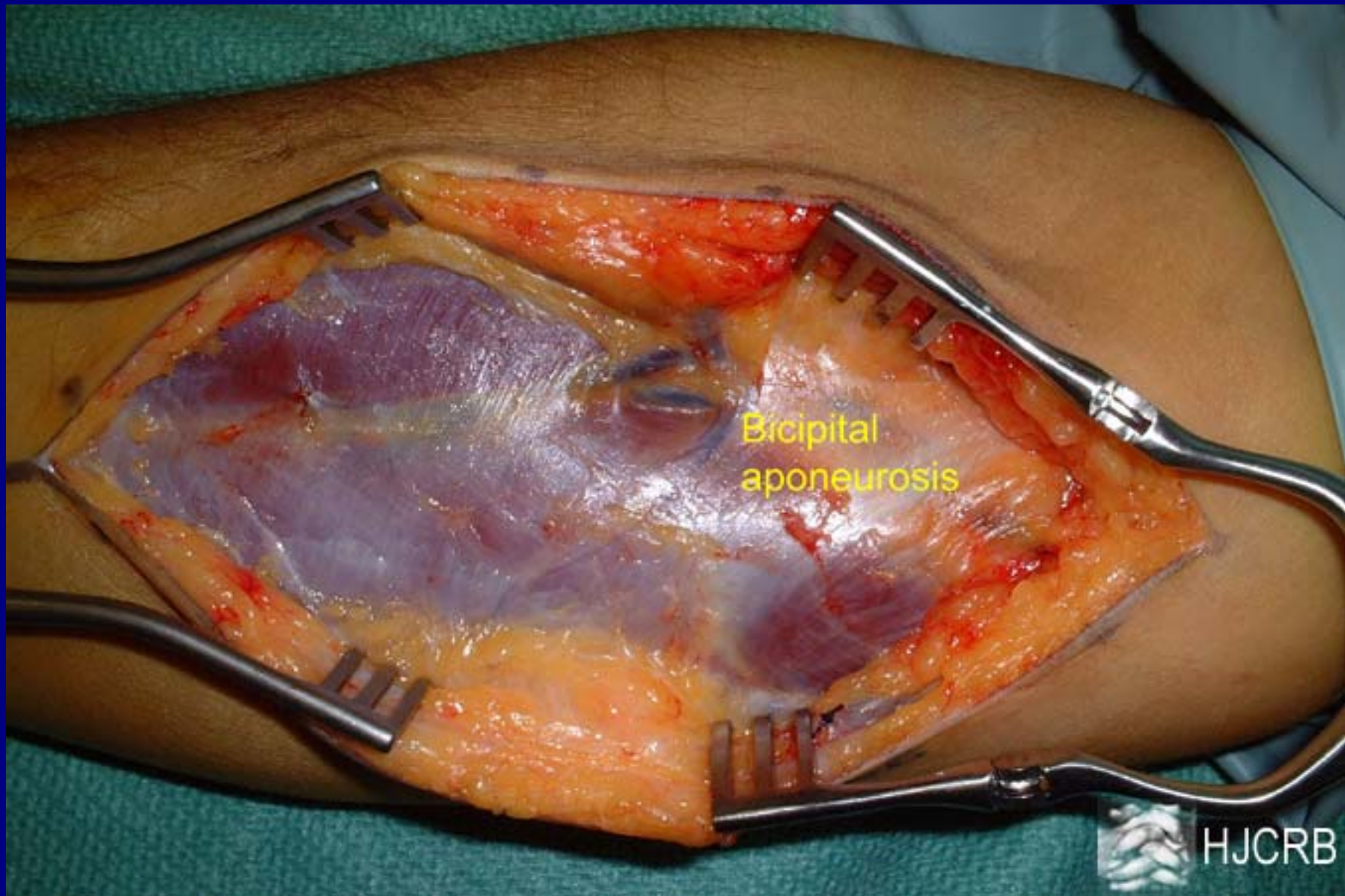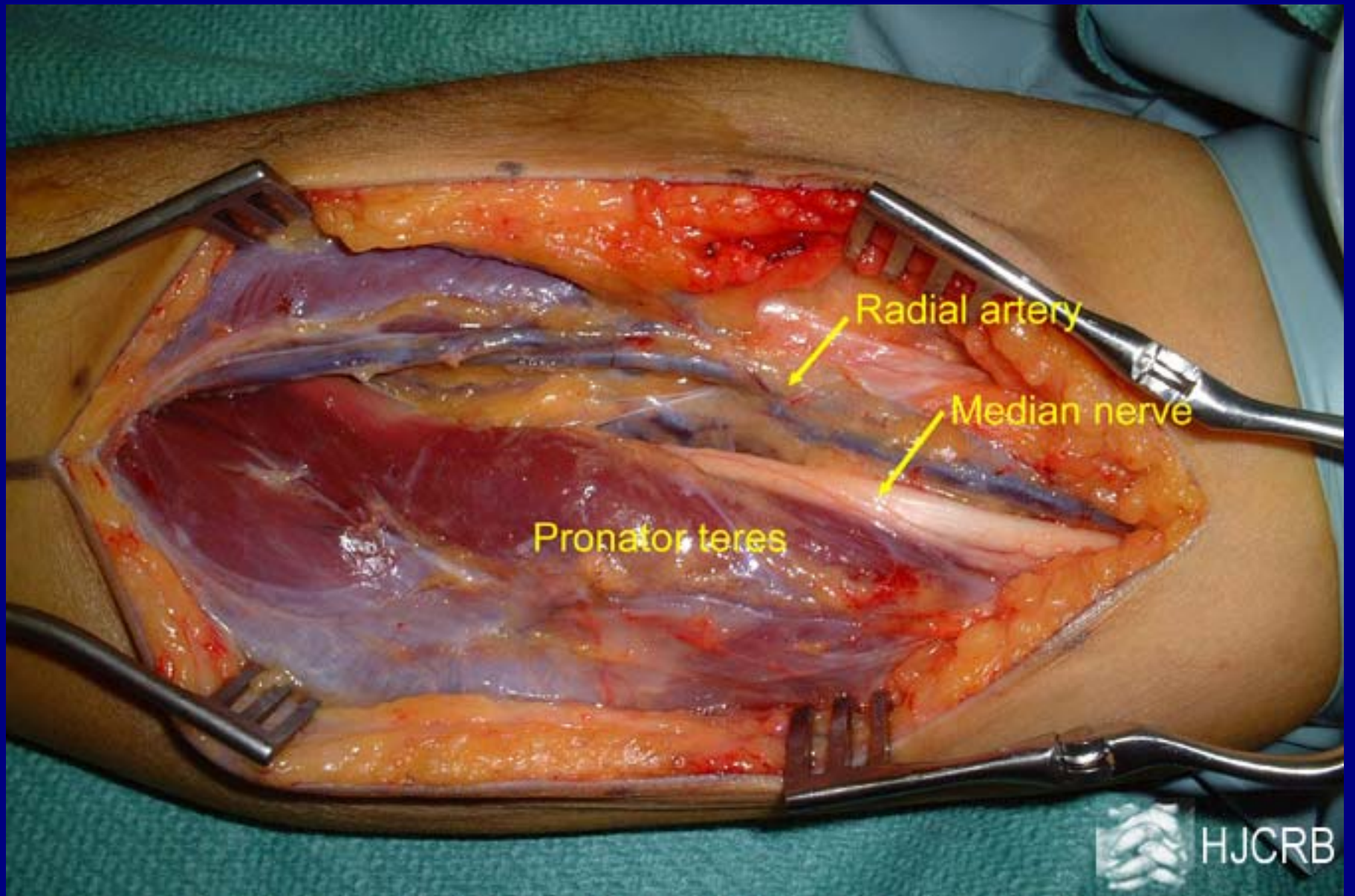


Bicipital
aponeurosis



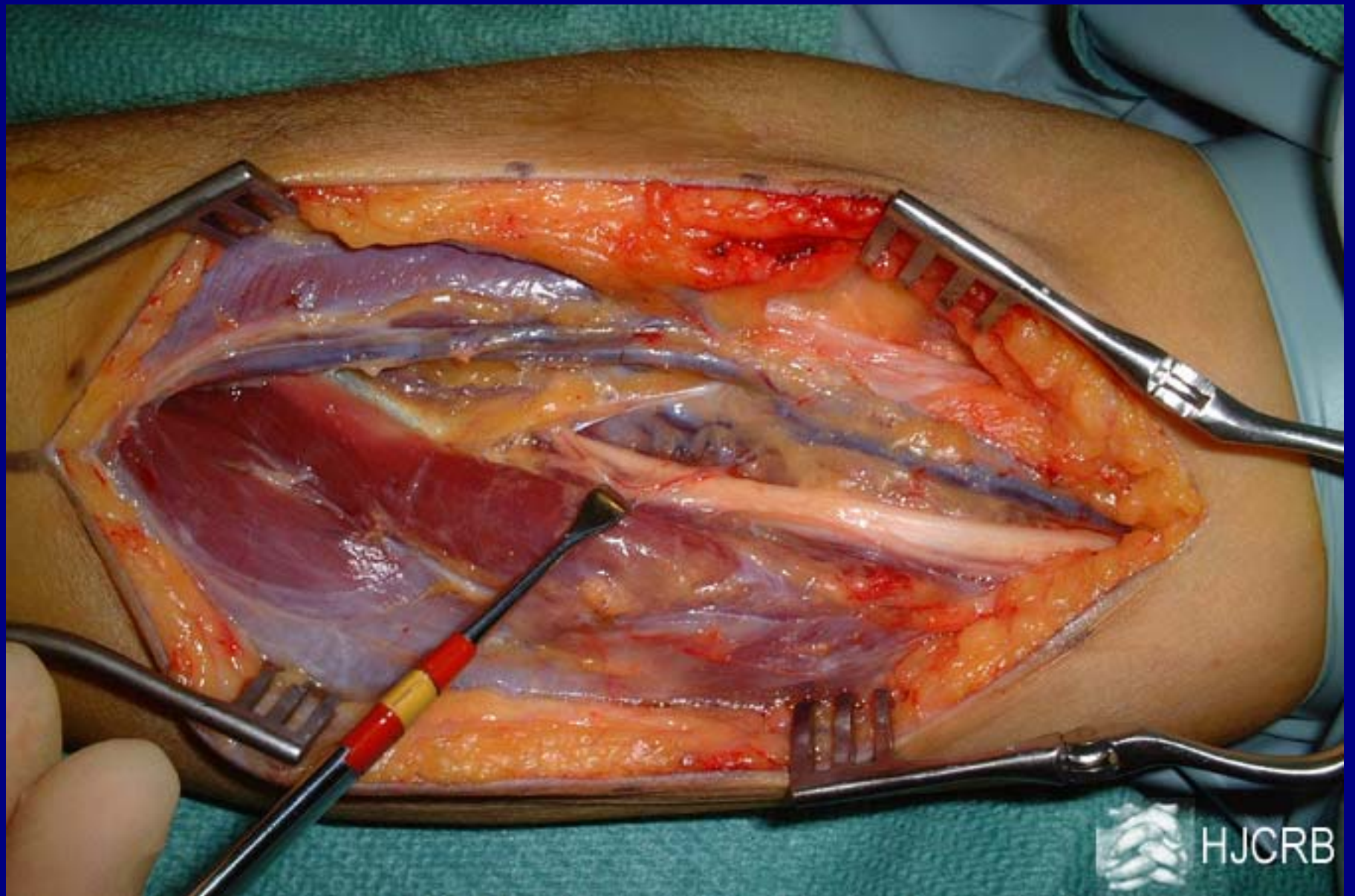
HJCRB

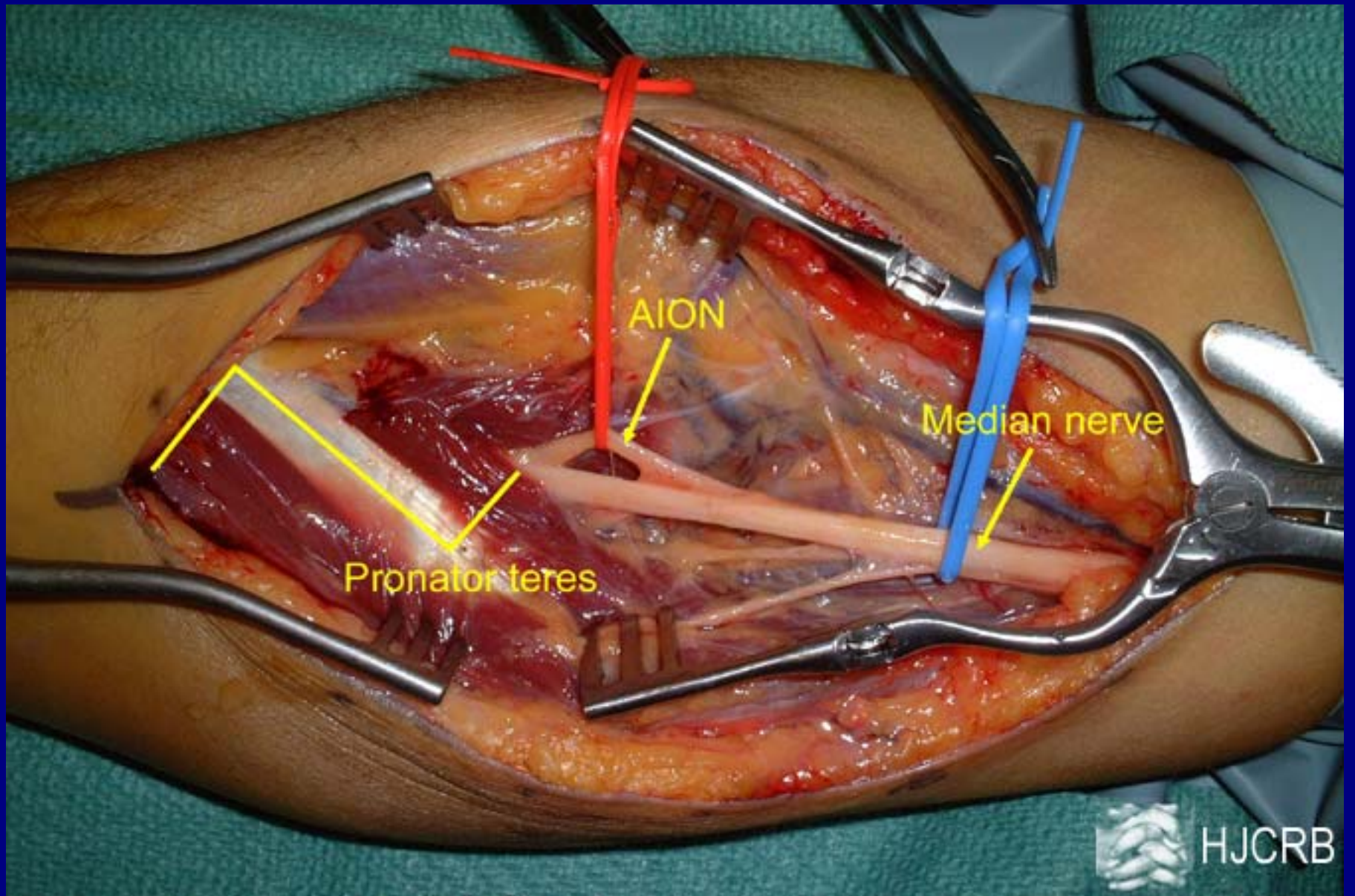


Radial artery

Median nerve

Pronator teres

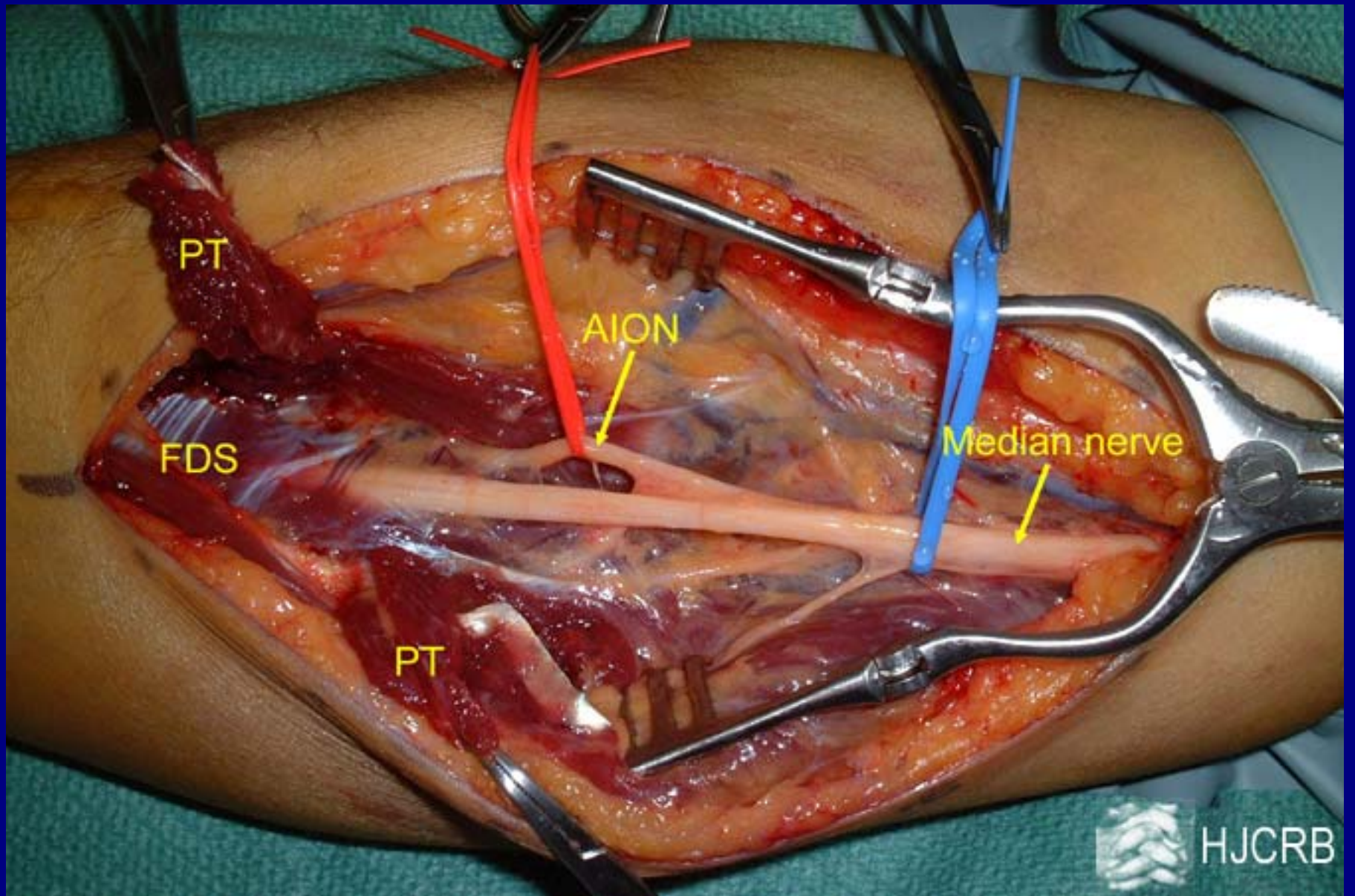




AION

Median nerve

Pronator teres



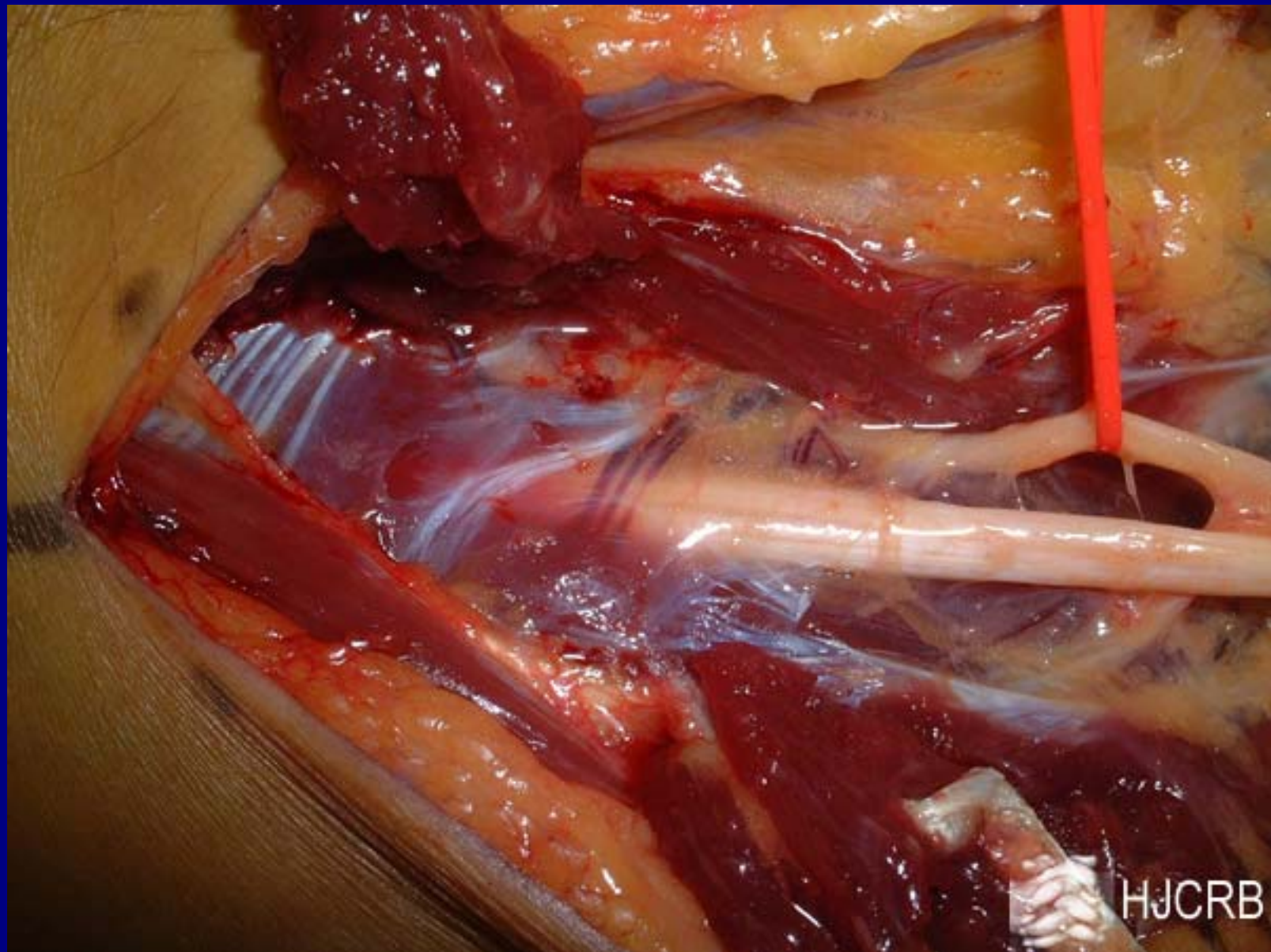
PT

AION

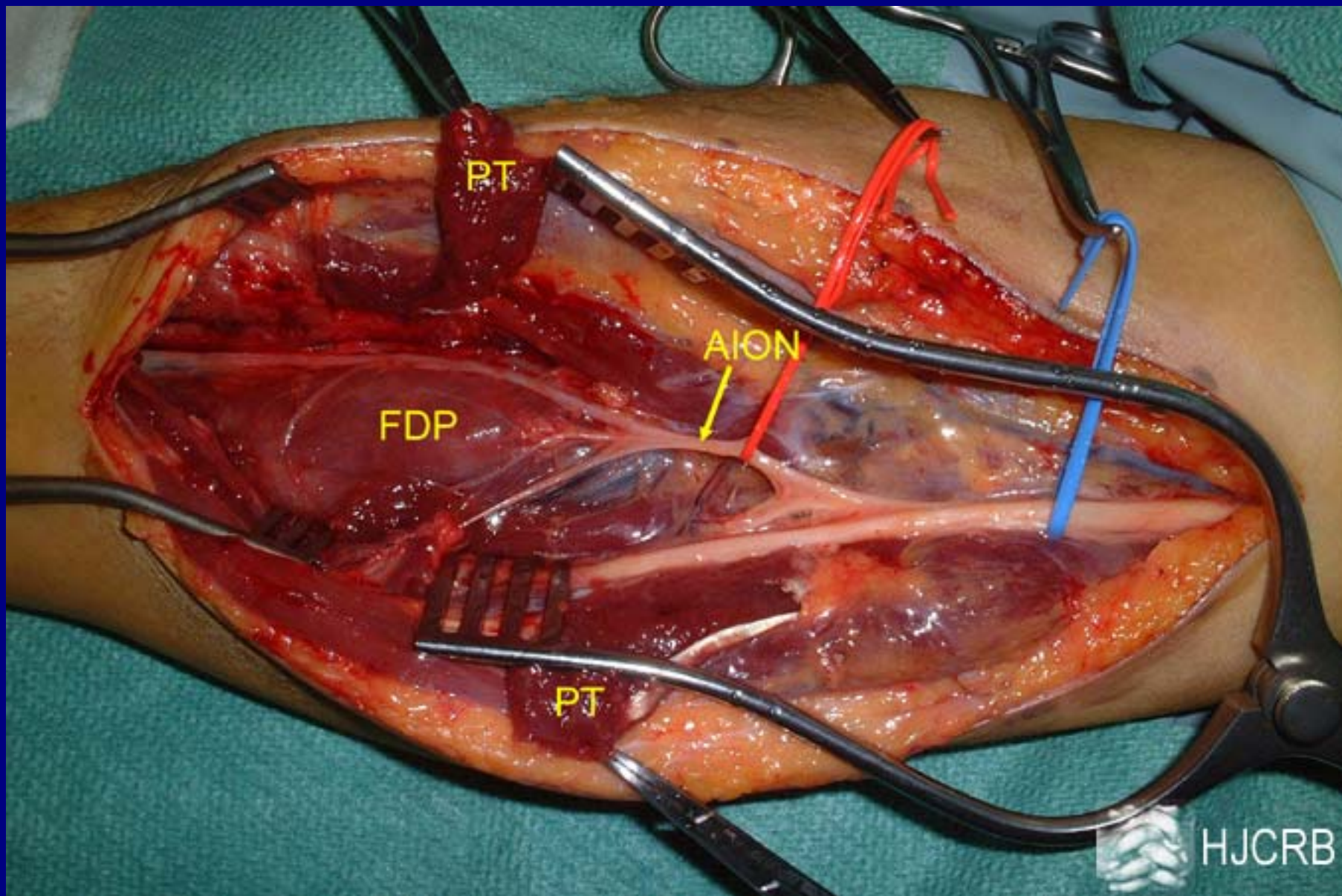
Median nerve

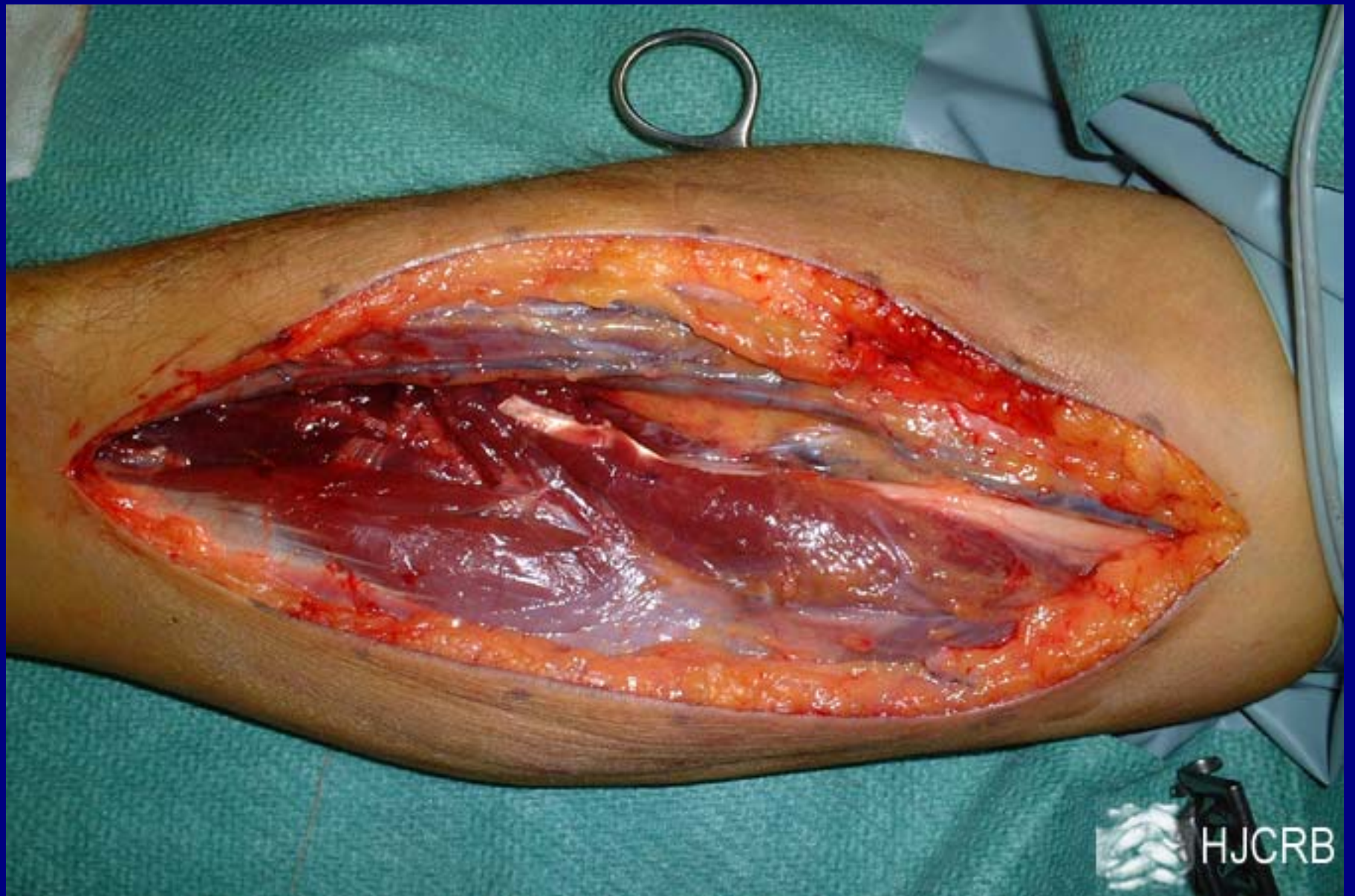
FDS

PT

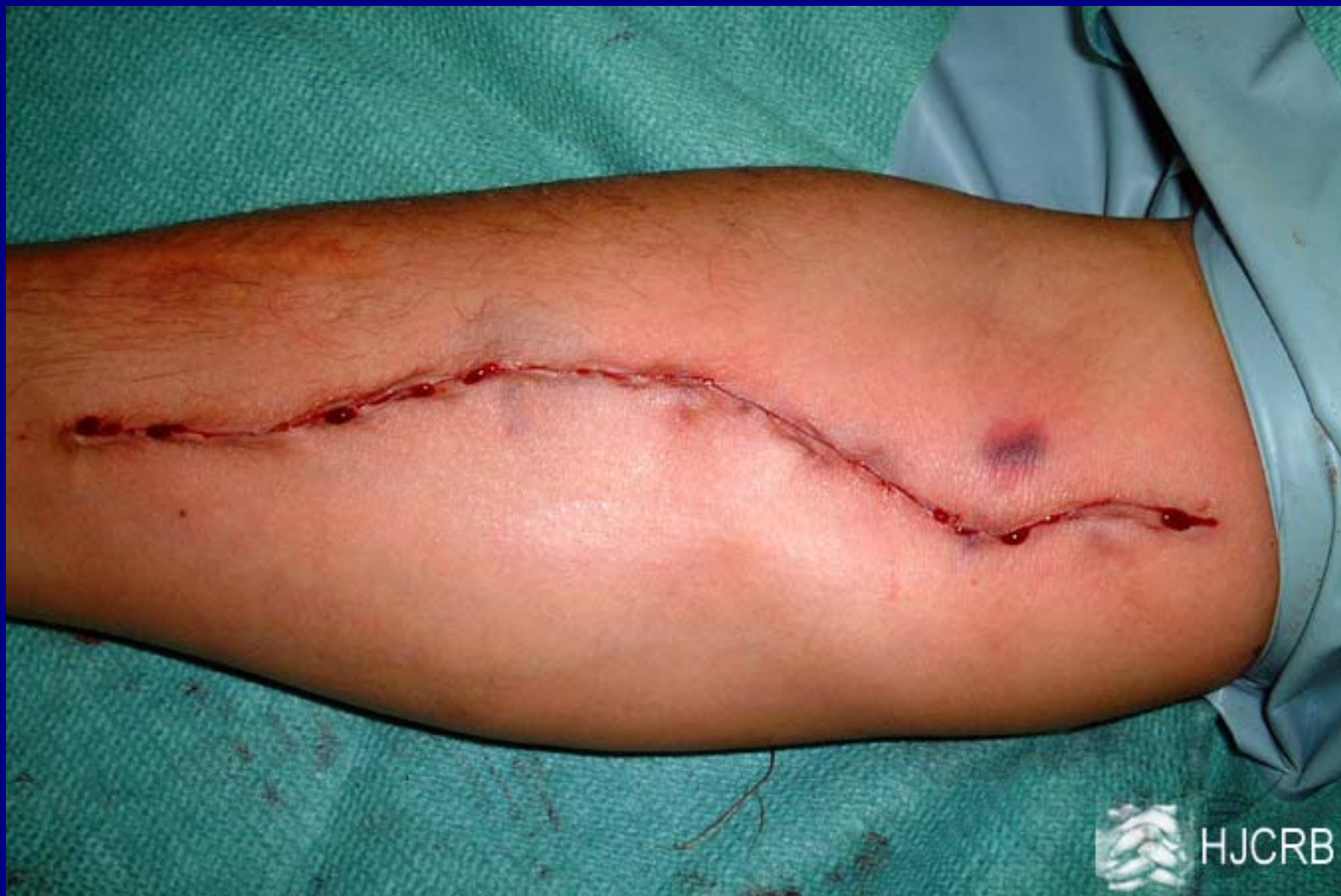

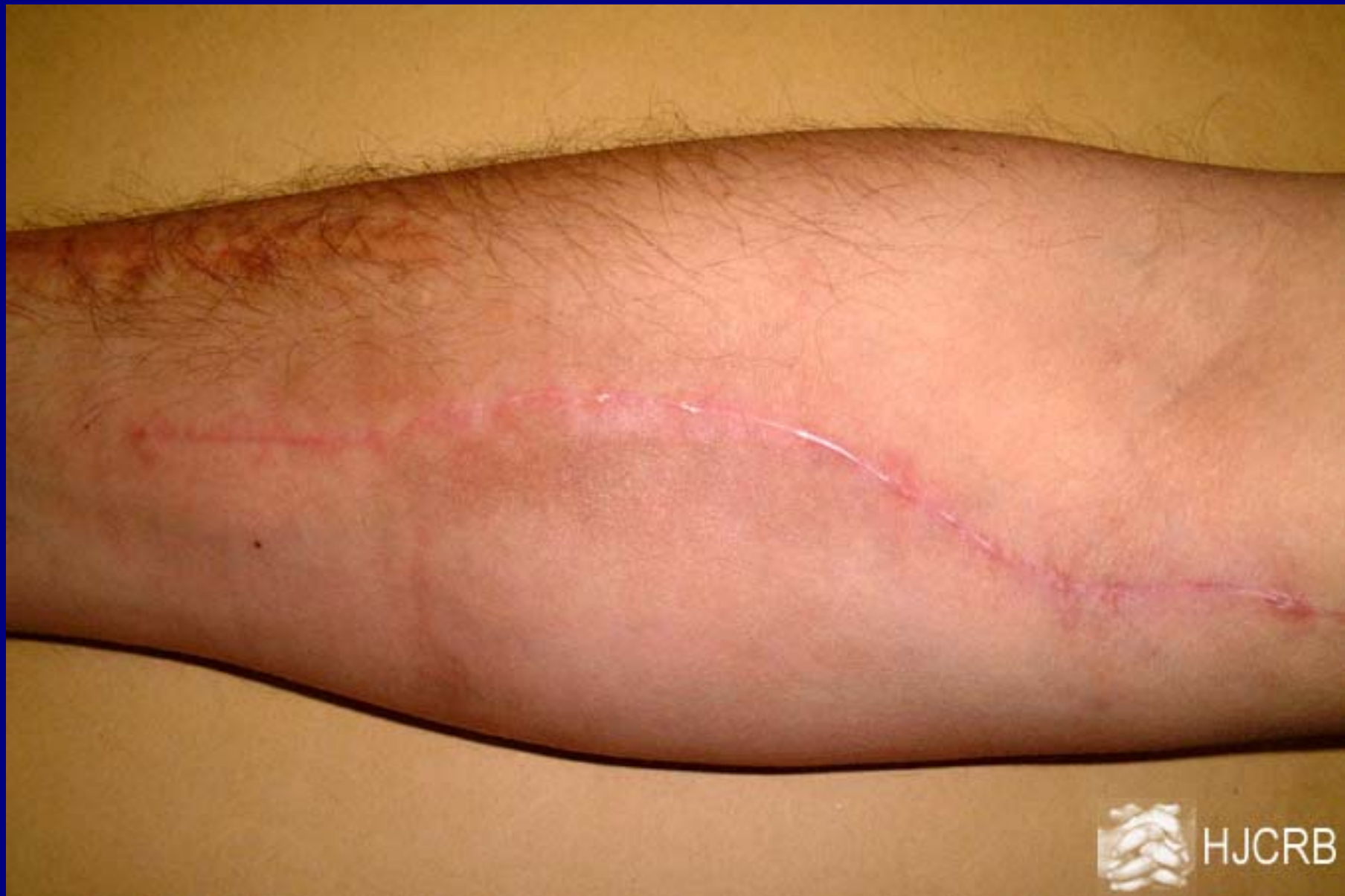HJCRB





HJCRB





HJCRB