

# Opponensplasty

FDS      Bunnell

PL      Camitz

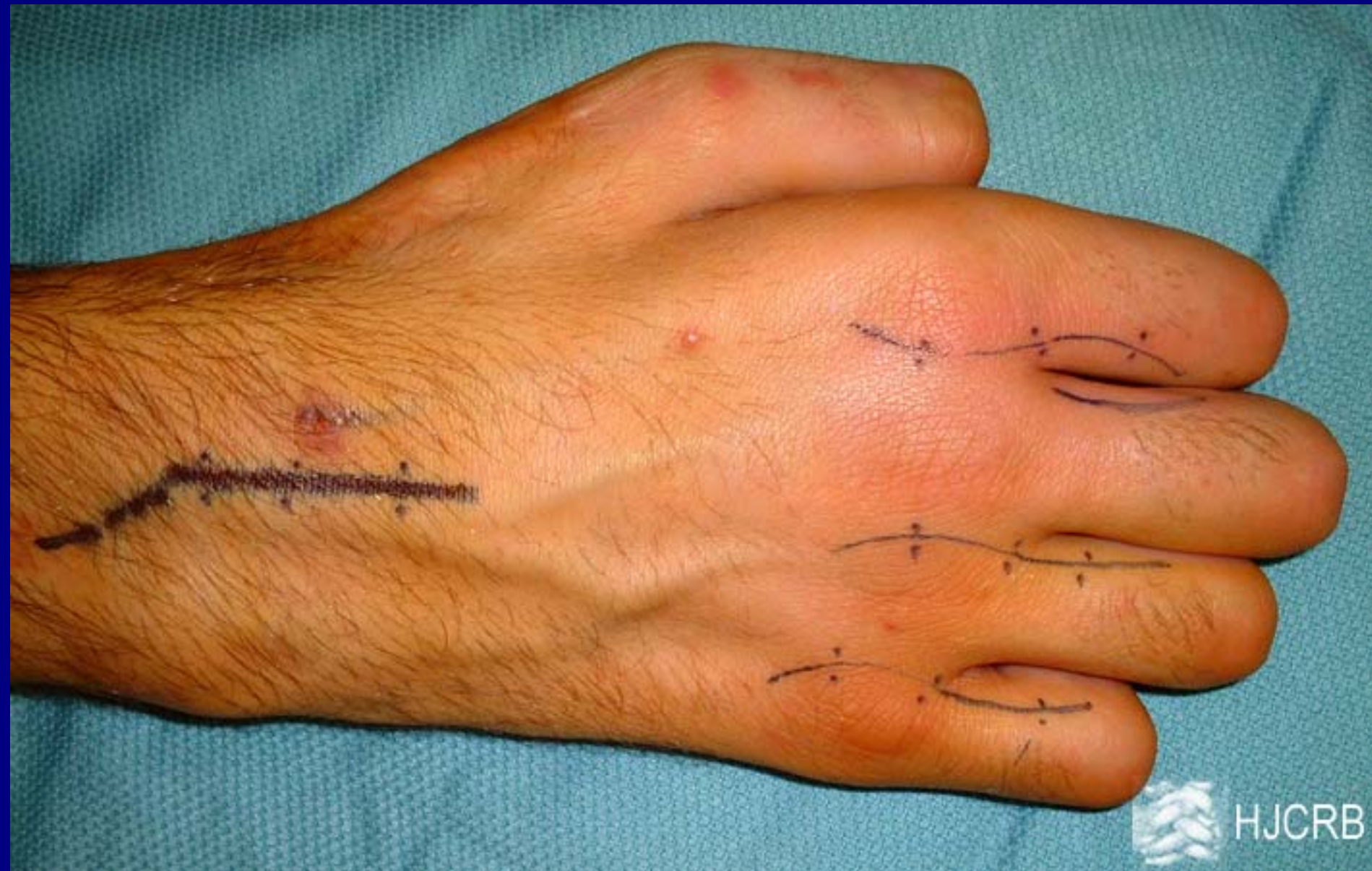
ADM      Huber

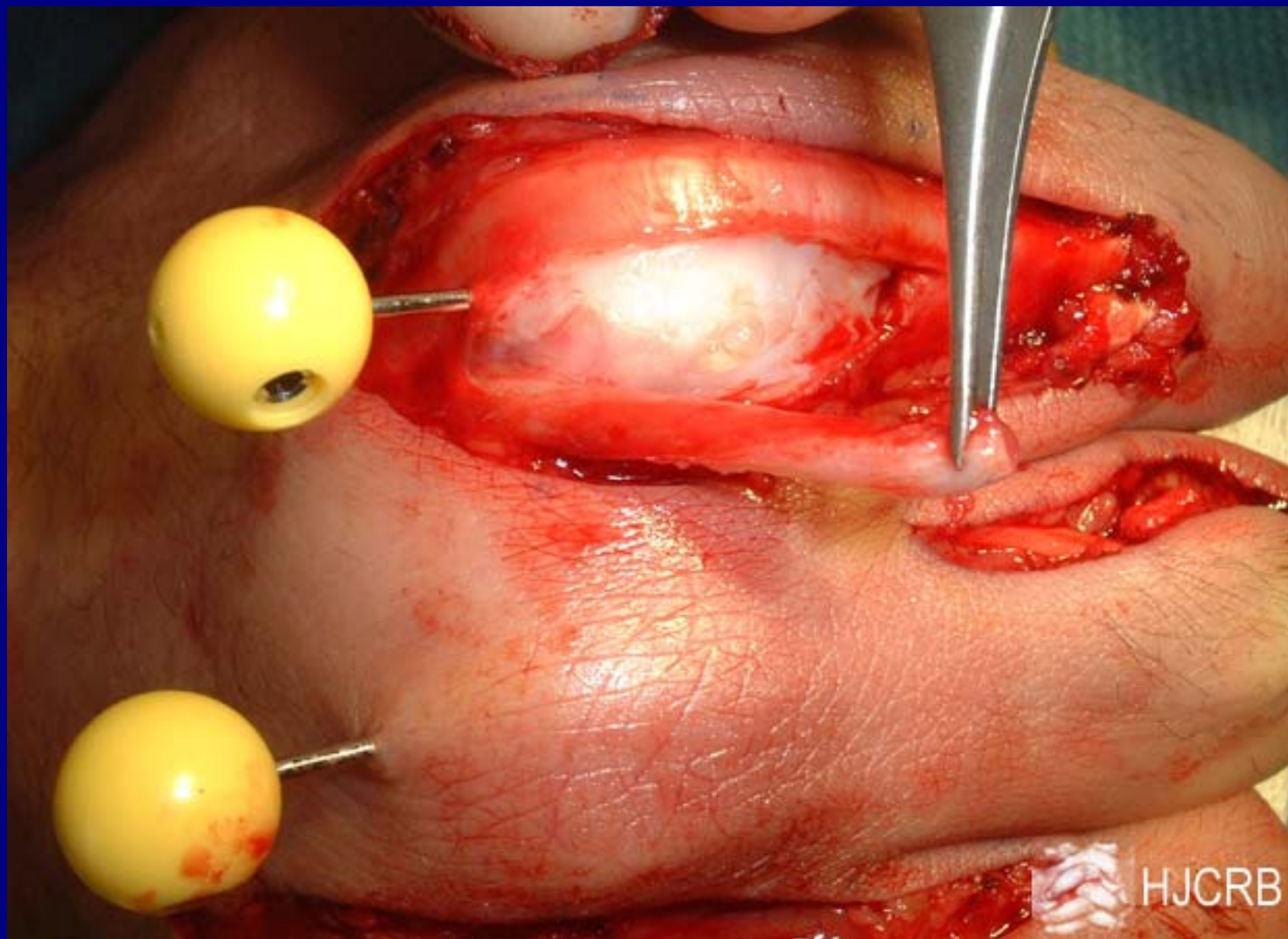
**EIP      Burkhalter**

Combined high median and ulnar palsy  
Clawing + Adduction deformity of thumb

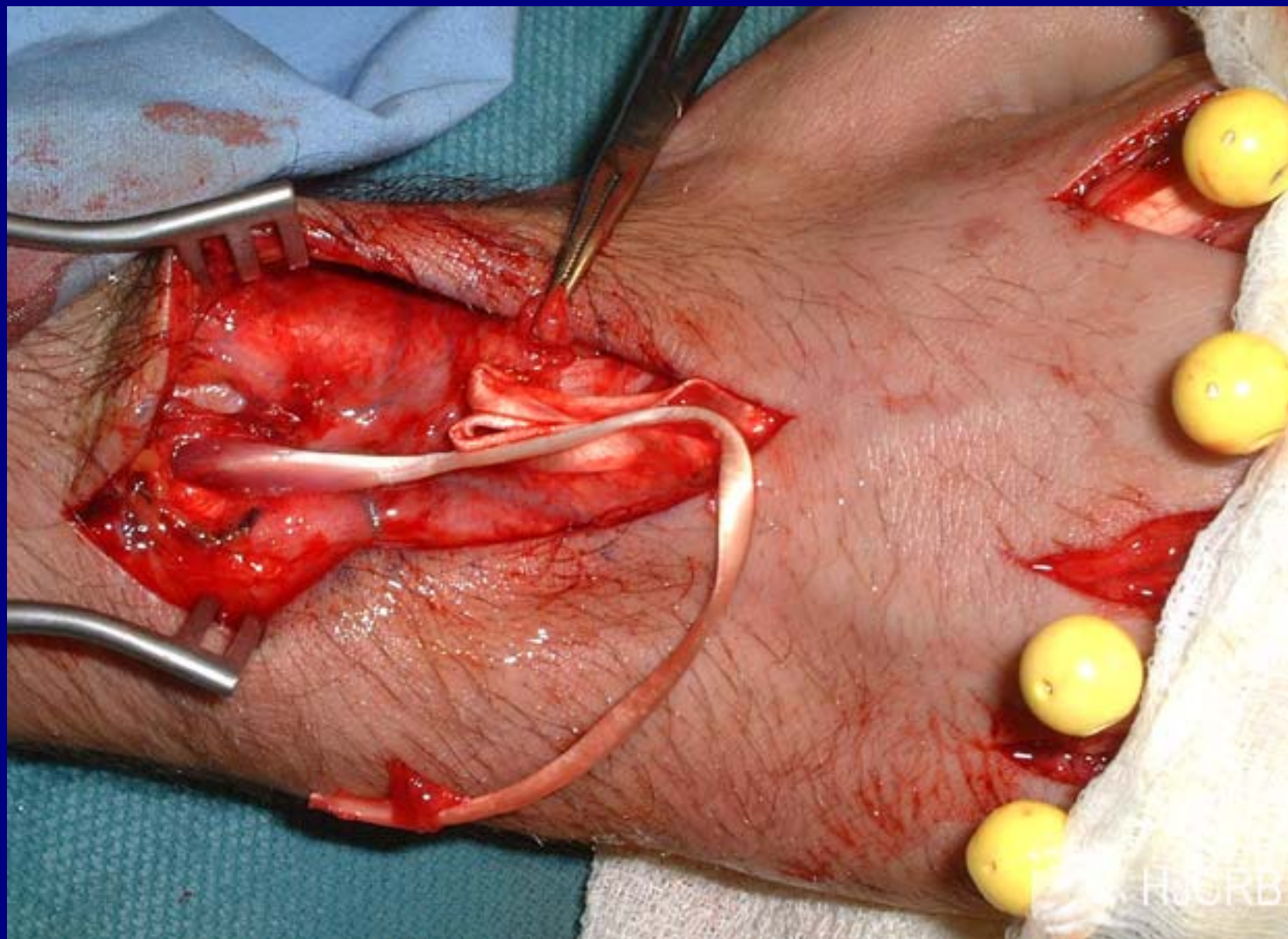
ECRL – PL graft – Extensor hood

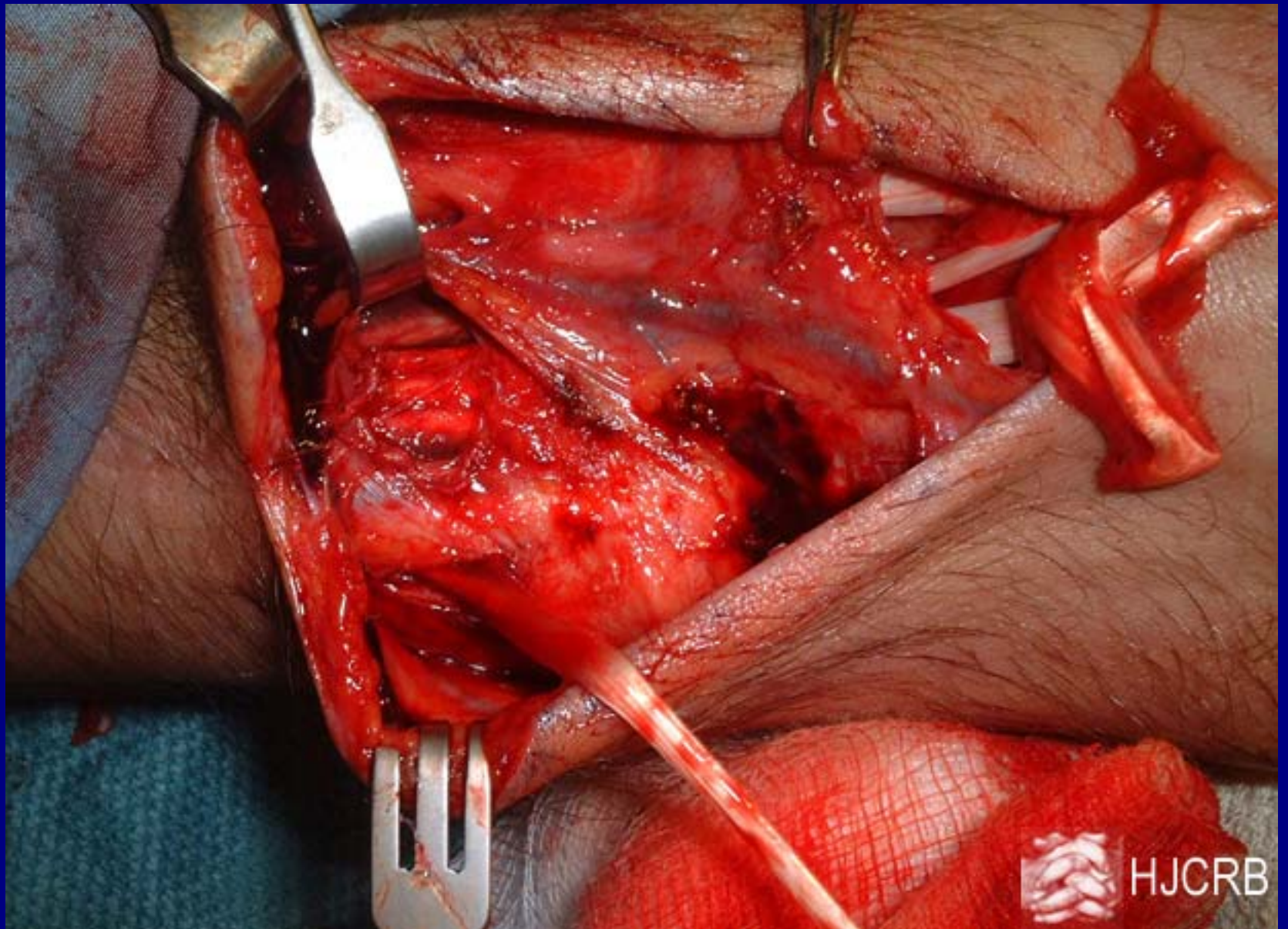
EIP opponensplasty

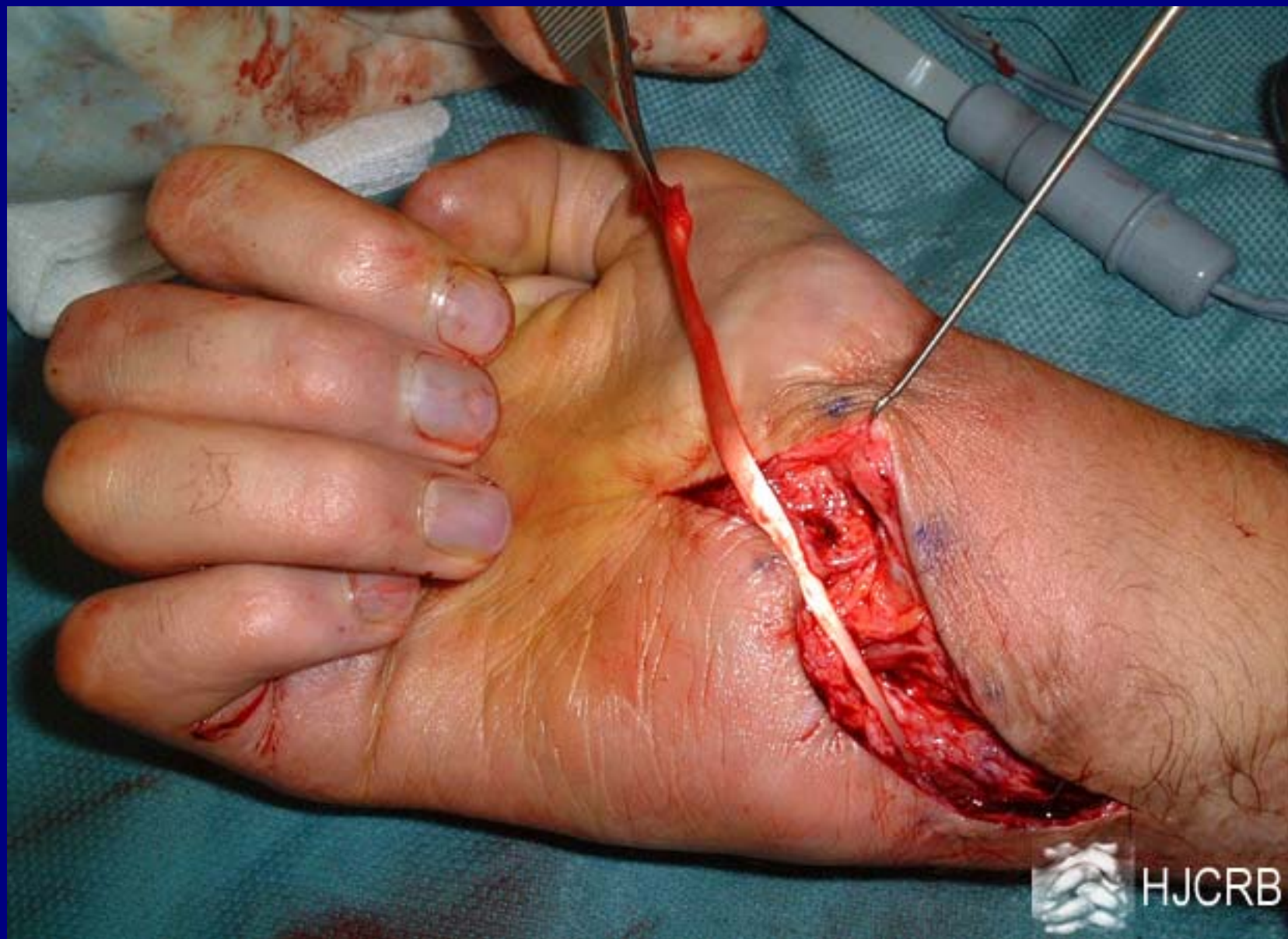


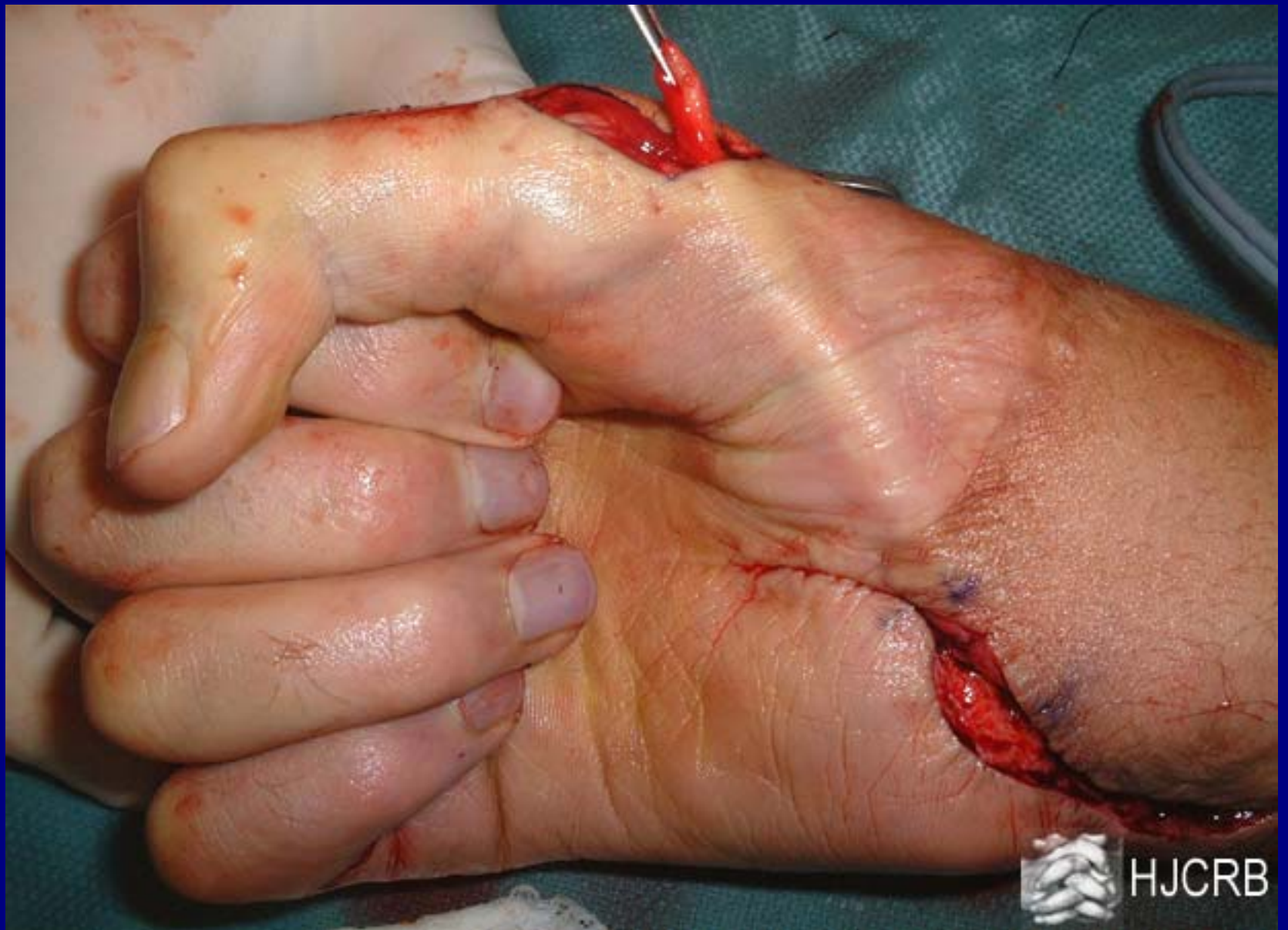
HJCRB









HJCRB