

# Opponensplasty

FDS      Bunnell

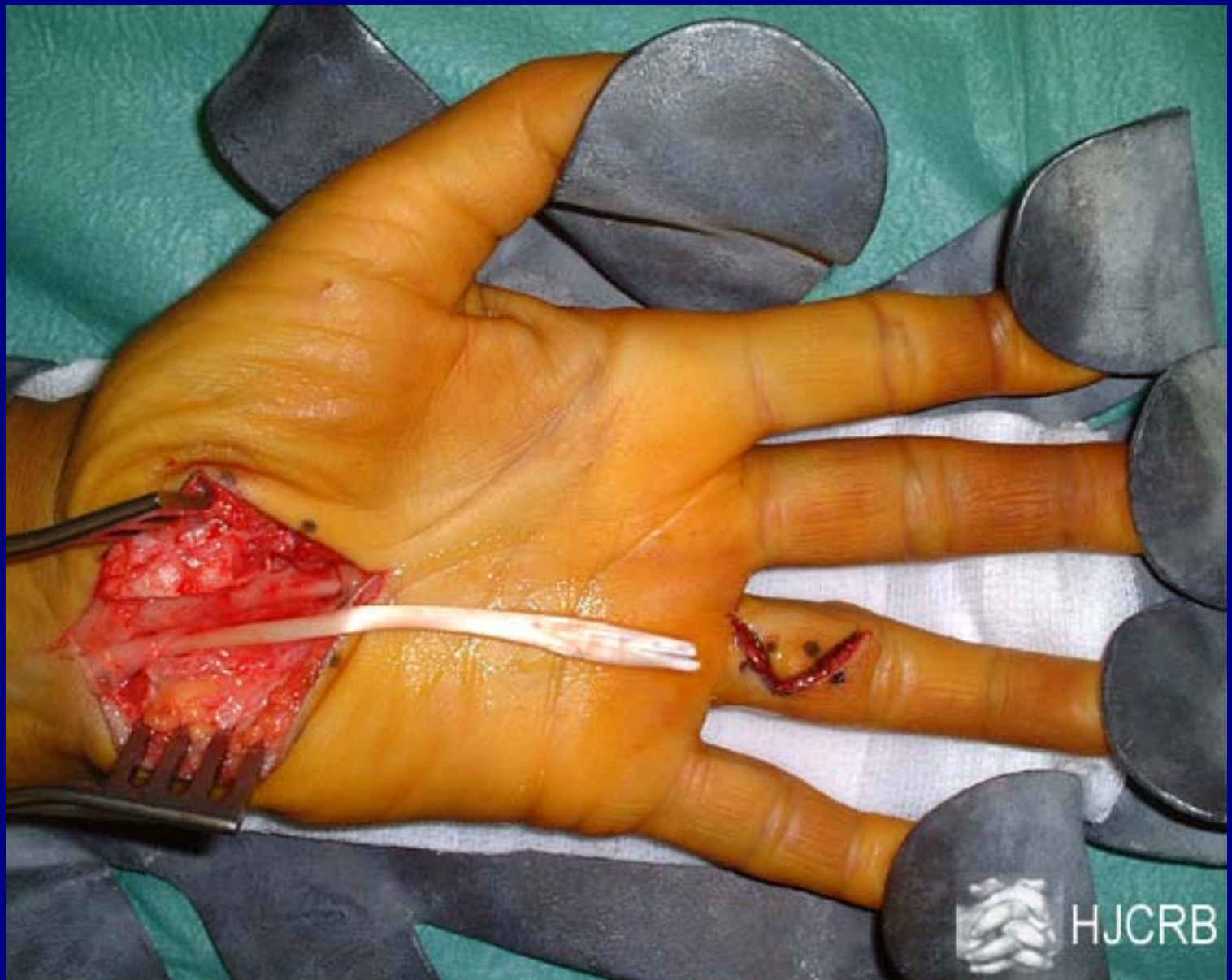PL      Camitz

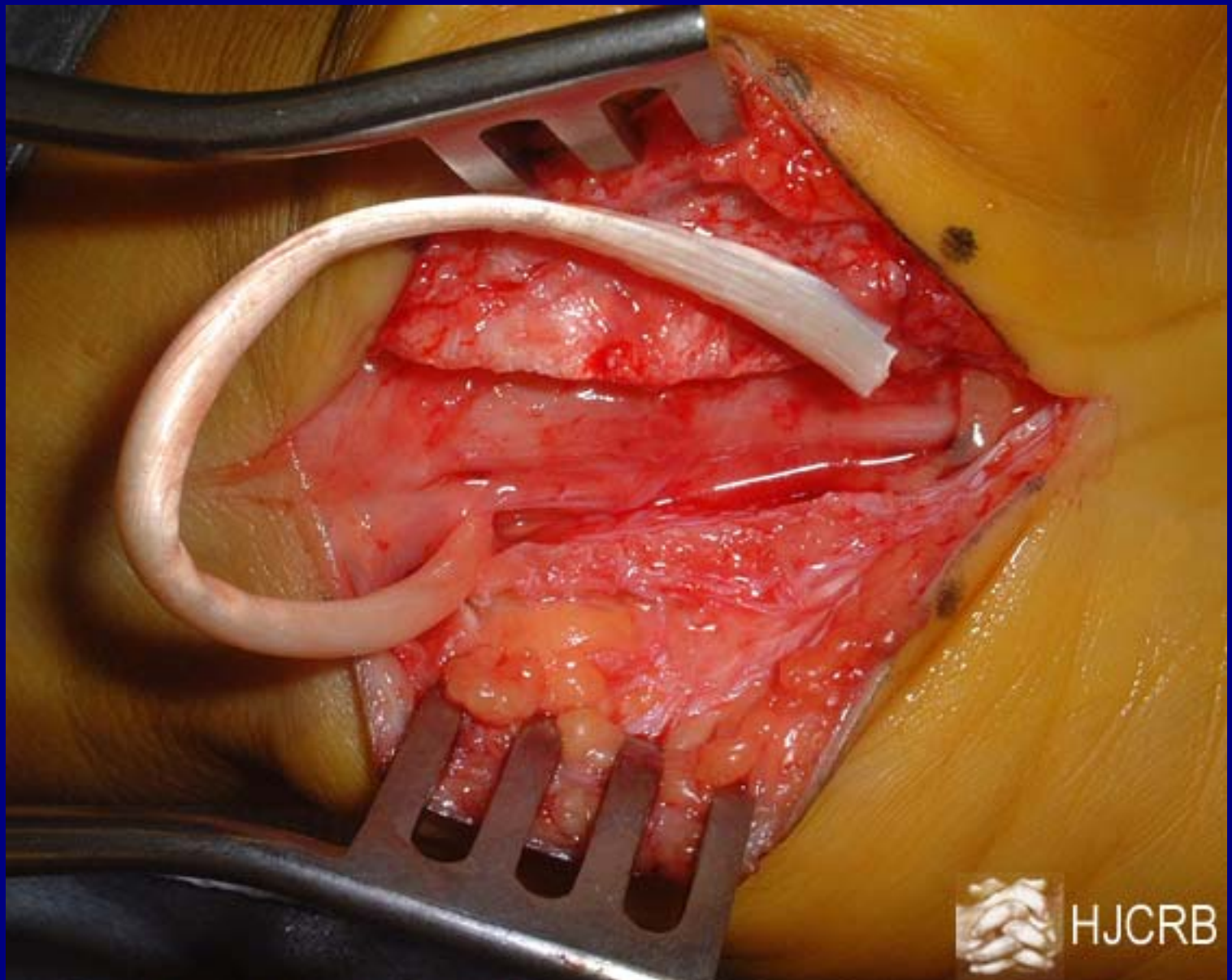
ADM      Huber

EIP      Burkhalter

Thenar muscle paralysis secondary to iatrogenic injury during a carpal tunnel release

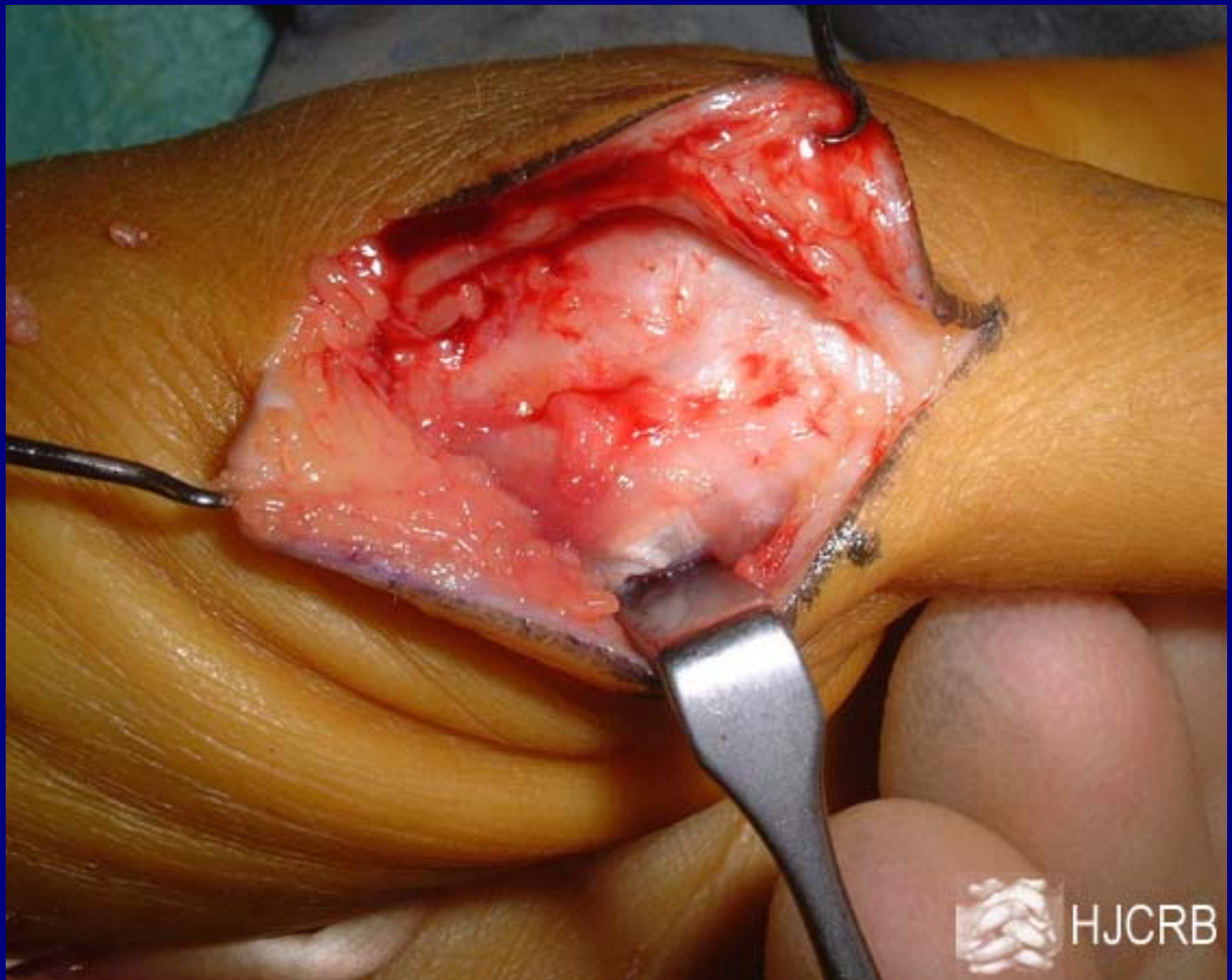
FDS transfer using the ulnar cut edge of the retinaculum as a pulley



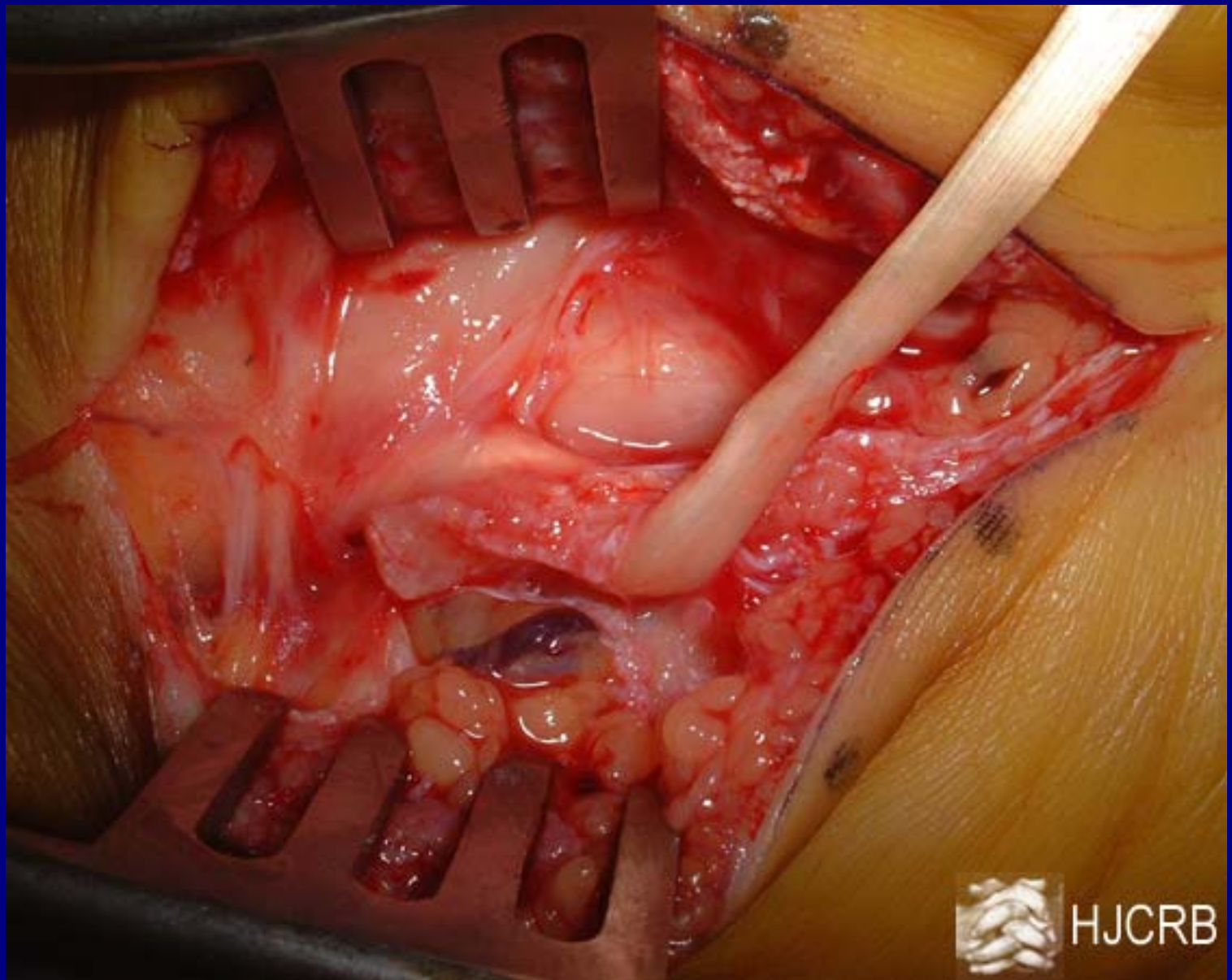


HJCRB



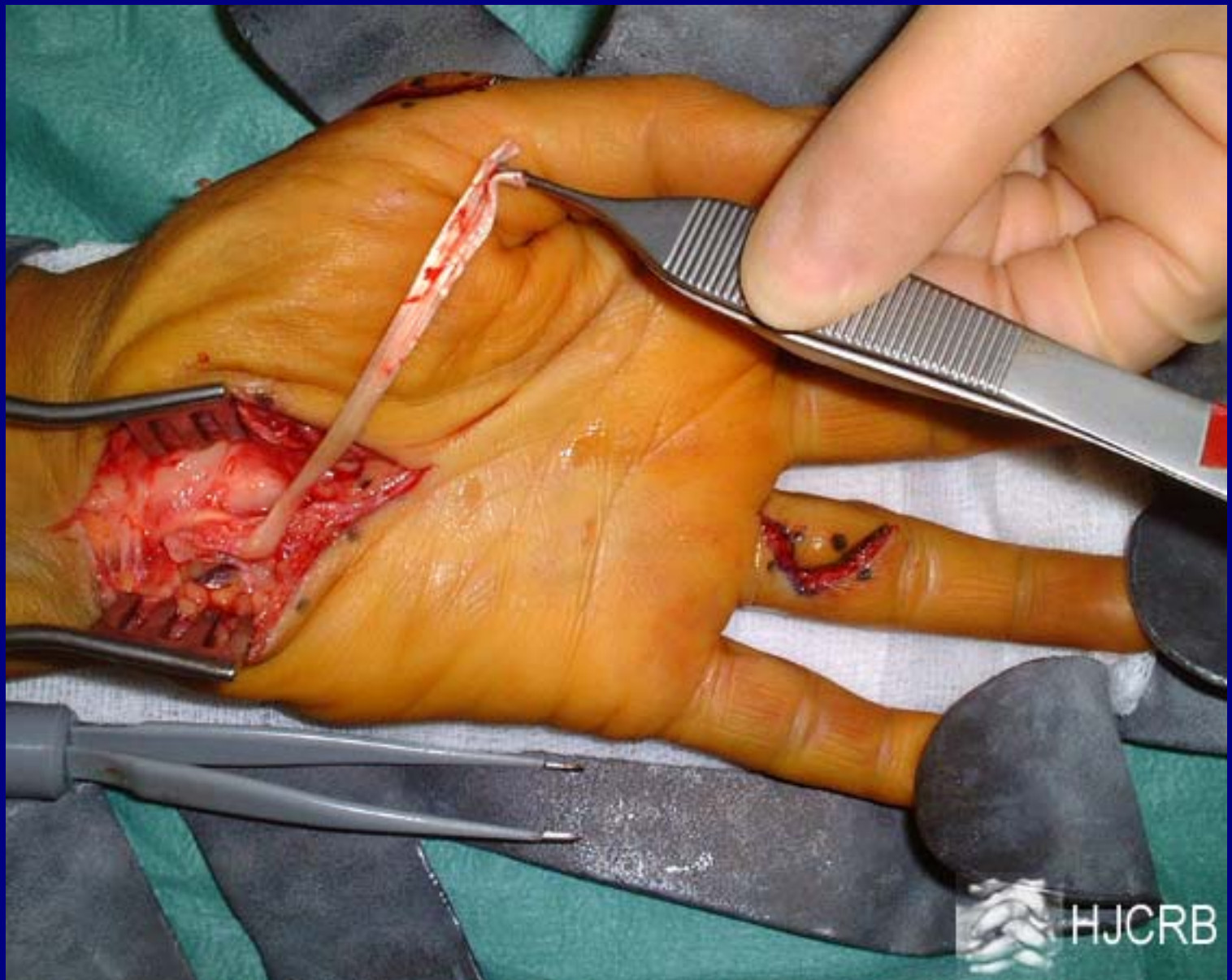


HJCRB

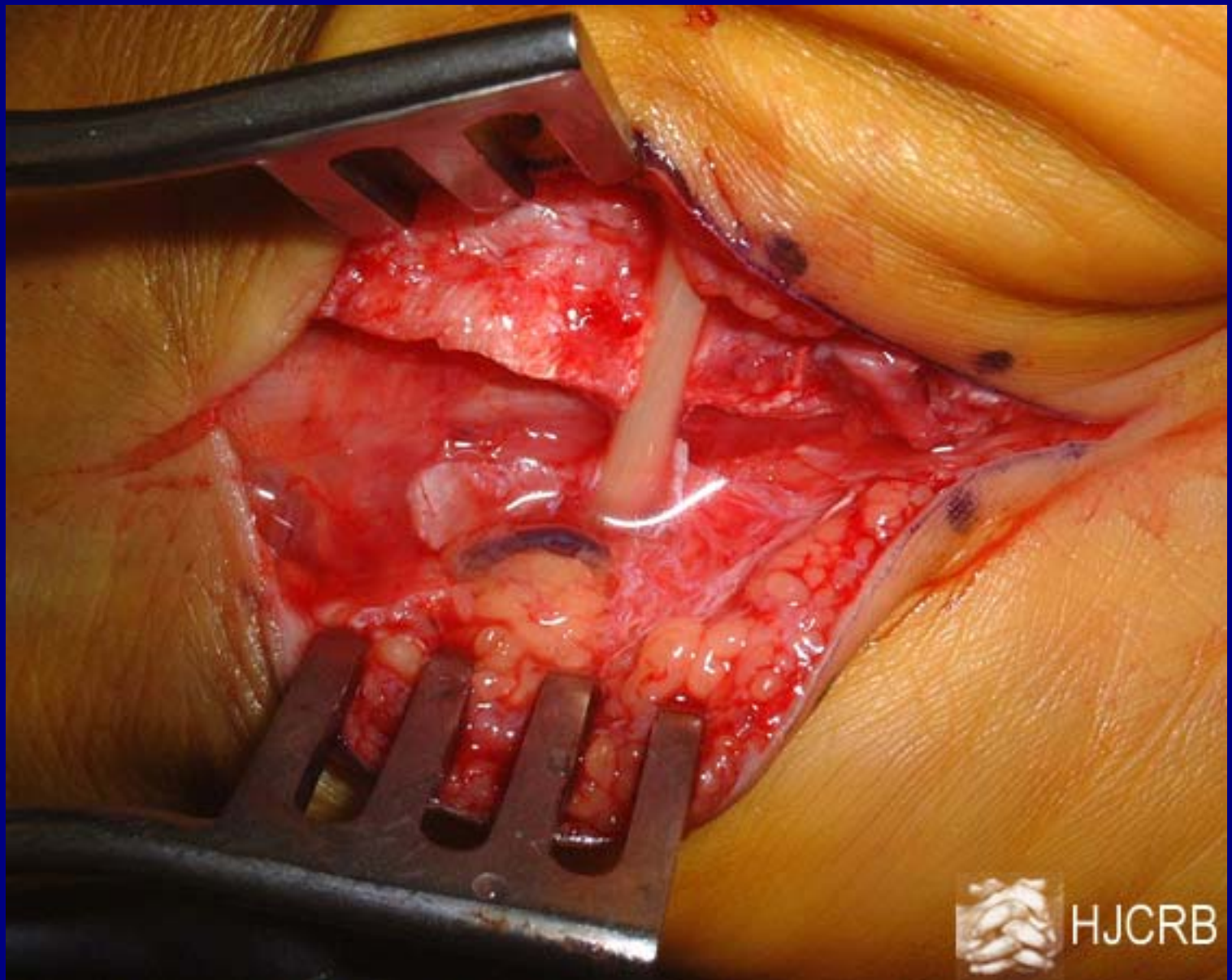


HJCRB



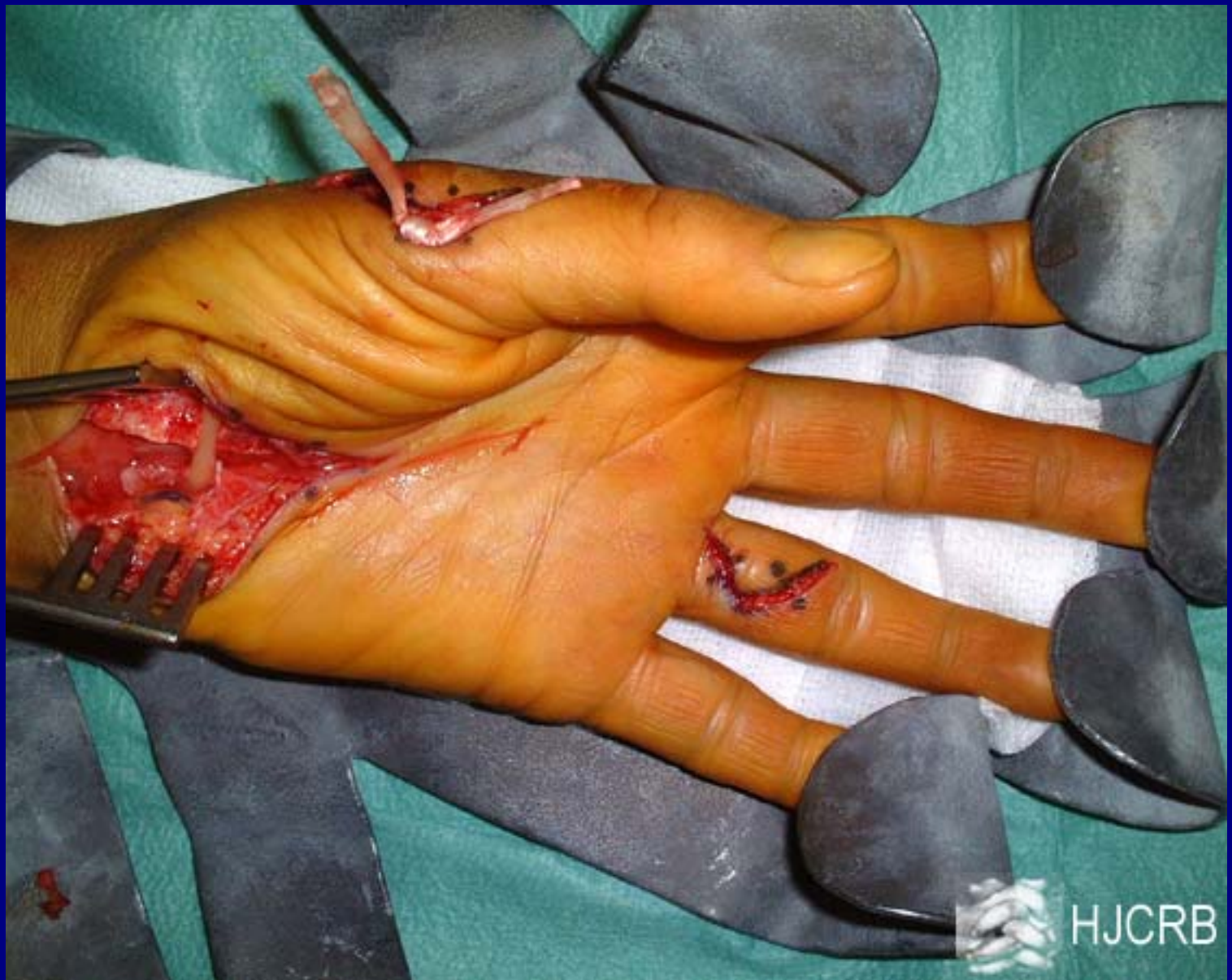

HJCRB



HJCRB





HJCRB

Thumb hypoplasia with poor thenar function  
and tight first web-space

FDS transfer using the distal edge of the  
retinaculum as a pulley supplemented by a  
4-flap Z-plasty





